

URINARY TRACT EXAMINATION IN CHILDREN

ANNA JAKUBOWSKA

IMAGING TECHNIQUES

- **ULTRASOUND (US)**
- **X- ray PLAIN FILM OF ABDOMEN**
- **VOIDING CYSTOURETHROGRAM (VCUG)**
- **INTRAVENOUS PYELOGRAPHY (IVP)**
- **NUCLEAR MEDICINE (NM)**
- **COMPUTER TOMOGRAPHY (CT)**
- **MAGNETIC RESONANCE (MRI)**
- **ANGIOGRAPHY**

INDICATIONS FOR UPPER URINARY TRACT EVALUATION

- URINARY TRACT INFECTION
- ABDOMINAL MASS
- ABDOMINAL PAIN (RECURENT) WITH CLINICAL SYMPTOMS OF UT DISEASE
- TRAUMA
- RENAL FAILURE
- HEMATURIA
- MALFORMATIONS ASSOCIATED WITH RENAL ANOMALIES

INDICATION FOR US

- **URINARY TRACT INFECTION**
- **ABNORMALITY DETECTED IN US PRENATALLY**
- **PRESENCE OR SUSPICION OF ABDOMINAL OR PELVIC MASS**
- **ABDOMINAL TRAUMA**
- **ACUTE, CHRONIC RENAL FAILURE**
- **NEPHROLITHIASIS**
- **ABDOMINAL PAIN**
- **HAEMATURIA**

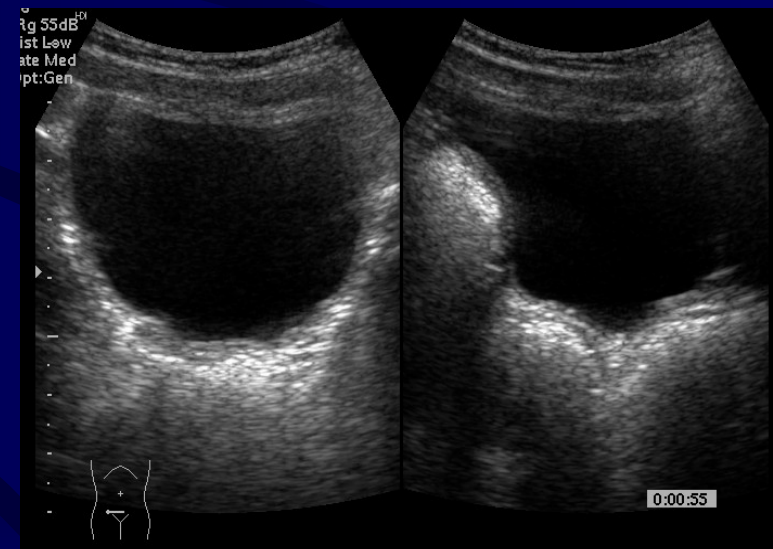
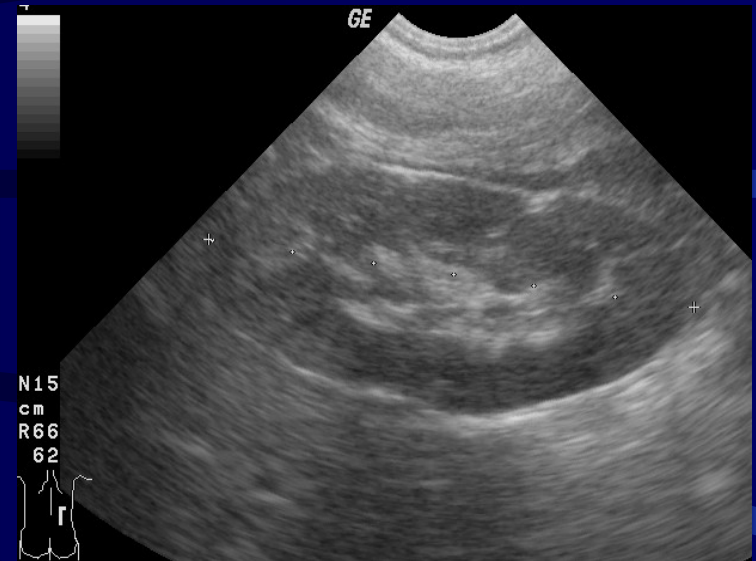
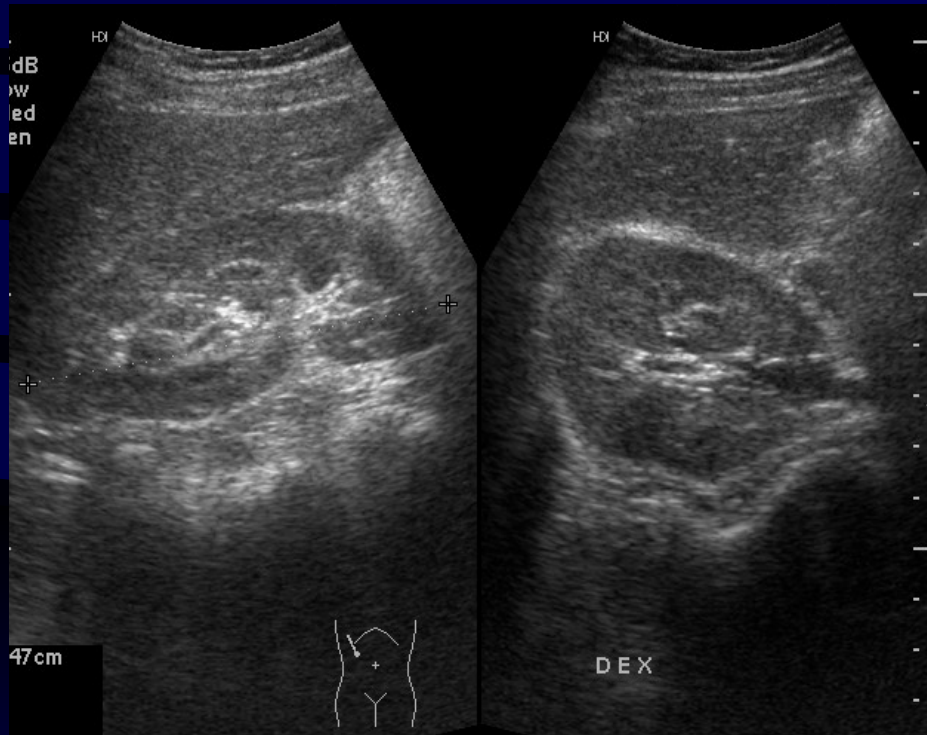
INDICATION FOR US

- **VOIDING PROBLEMS**
- **FOLLOW-UP EVALUATION AFTER SURGERY UT**
- **MALFORMATIONS ASSOCIATED WITH RENAL ANOMALIES**
 - **IMPERFORATE ANUS**
 - **ANOMALIES OF THE REPRODUCTIVE SYSTEM**
 - **ANOMALIES OF THE VERTEBRAL COLUMN**
- **CONDITONS THAT PREDISPOSE TO RENAL TUMOR**

DIAGNOSTIC CRITERIA IN US URINARY TRACT

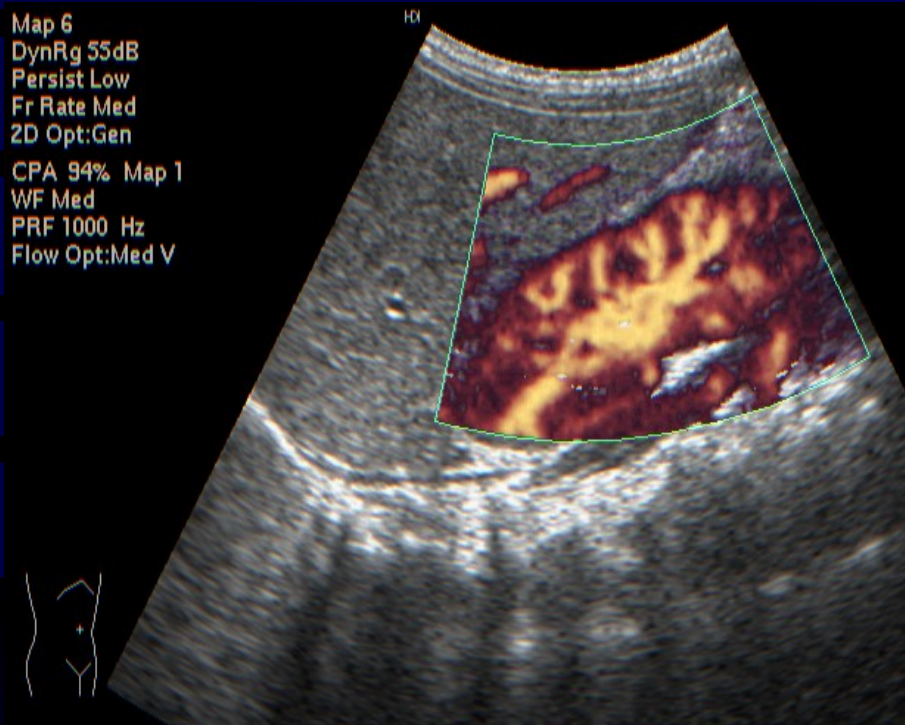
- **RENAL LOCALIZATION**
- **RENAL SIZE**
- **ECHOGENICITY OF RENAL PARENCHYMA**
- **CORTICO--MEDULLARY DIFFERENTIATION**
- **DILATATION OF COLLECTING SYSTEM**
- **MORPHOLOGY AND DYNAMICS OF URETERS**
- **BLADDER SIZE, RESIDUAL VOLUME**
- **BLADDER WALL**

NORMAL US OF URINARY TRACT

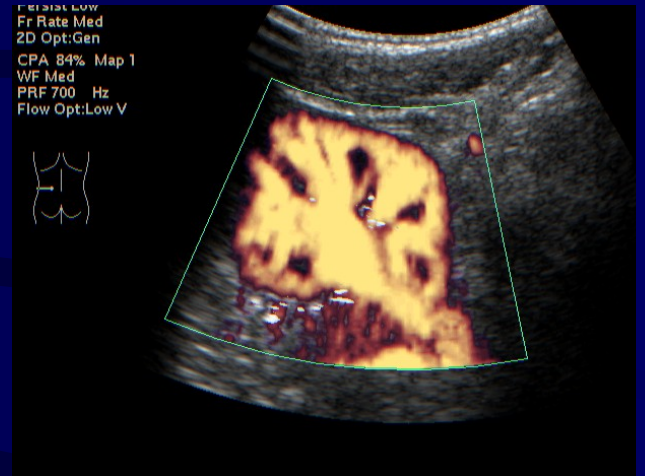


NORMAL „POWER POPPLER” OF KIDNEY

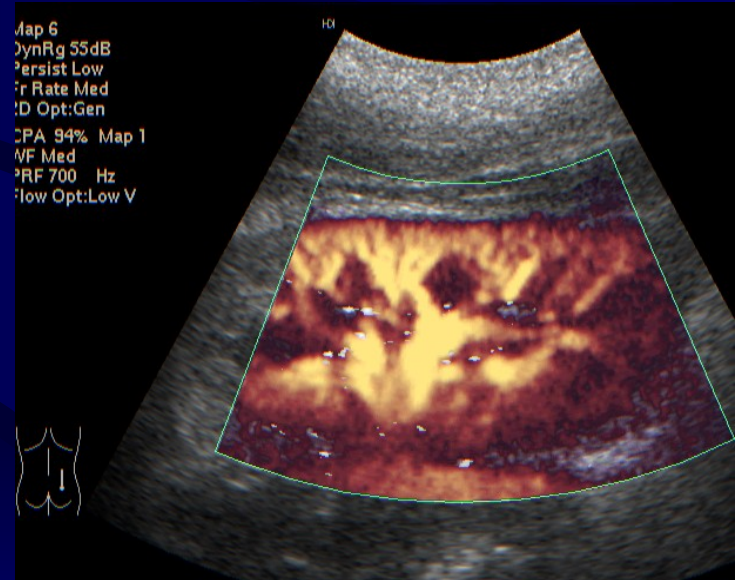
Map 6
DynRg 55dB
Persist Low
Fr Rate Med
2D Opt:Gen
CPA 94% Map 1
WF Med
PRF 1000 Hz
Flow Opt:Med V



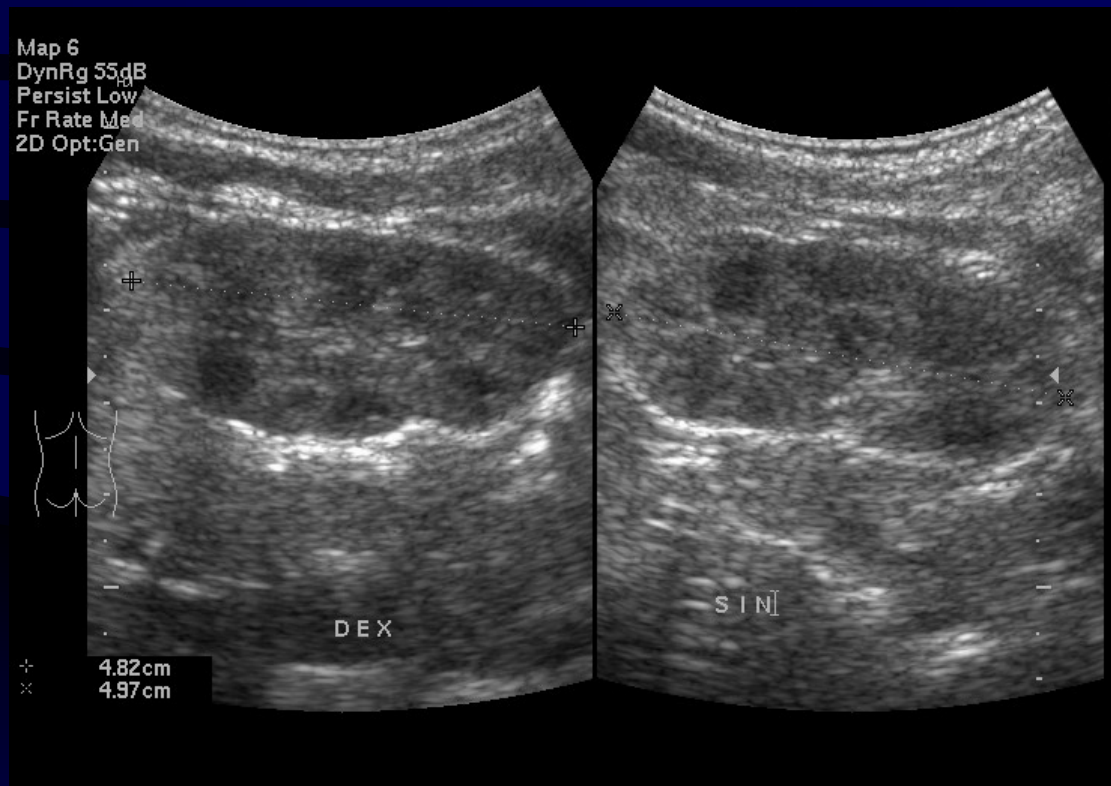
Persist Low
Fr Rate Med
2D Opt:Gen
CPA 84% Map 1
WF Med
PRF 700 Hz
Flow Opt:Low V



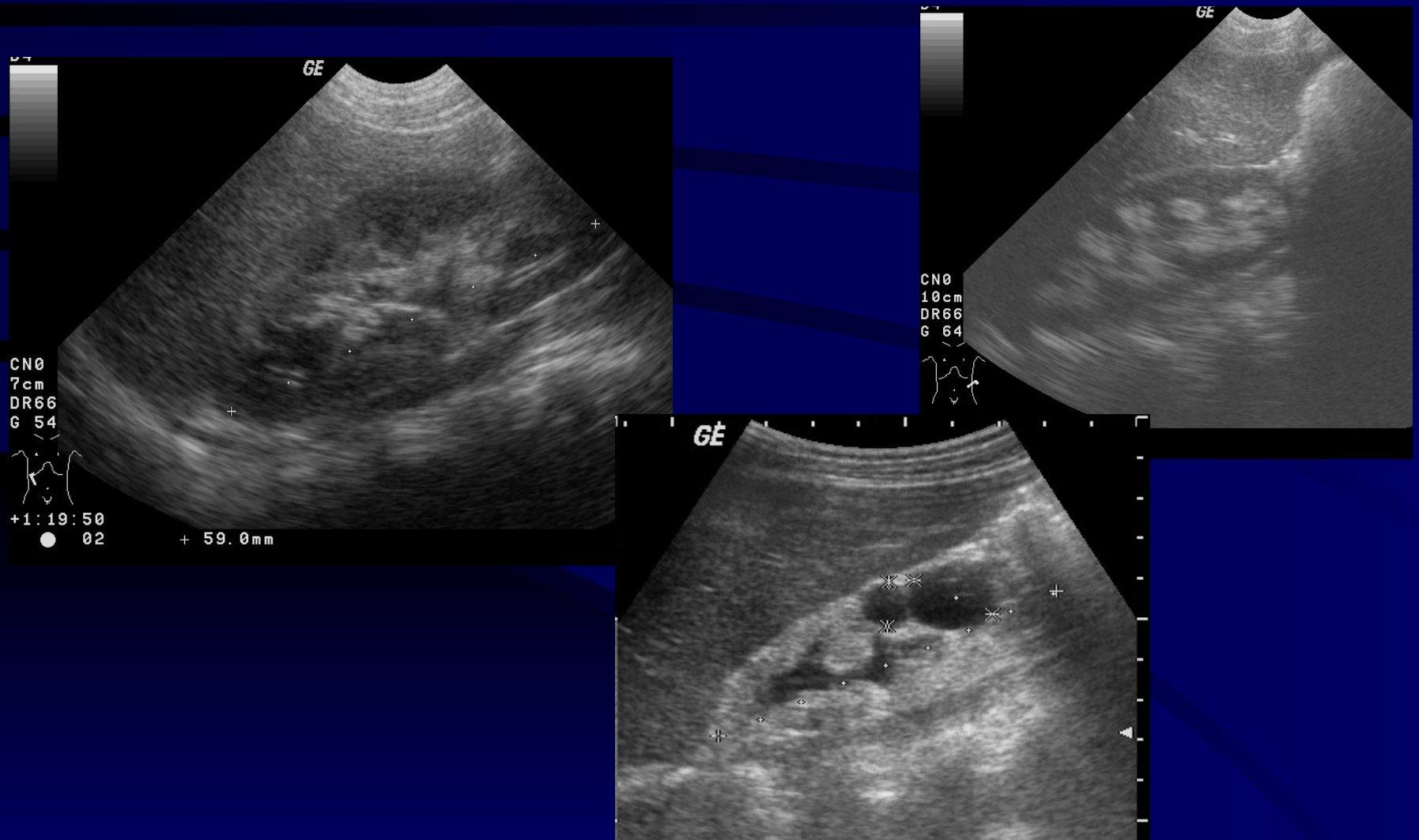
Map 6
DynRg 55dB
Persist Low
Fr Rate Med
2D Opt:Gen
CPA 94% Map 1
WF Med
PRF 700 Hz
Flow Opt:Low V



NEONATAL KIDNEY

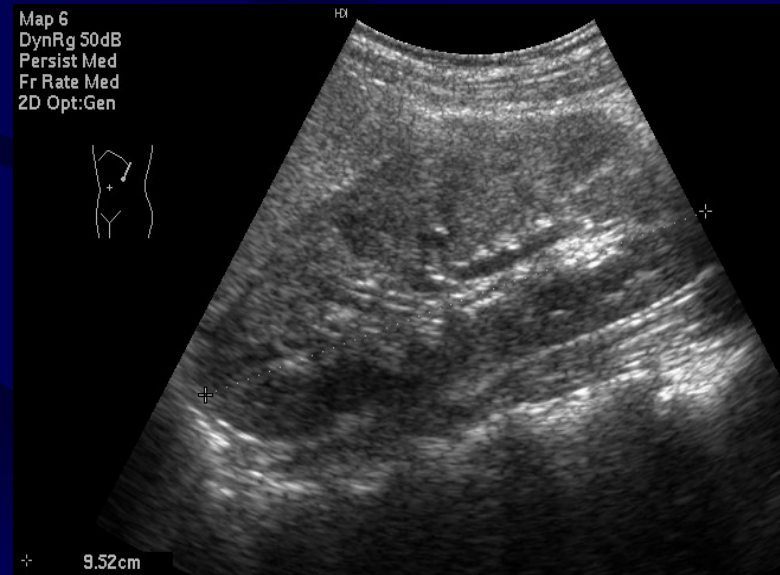
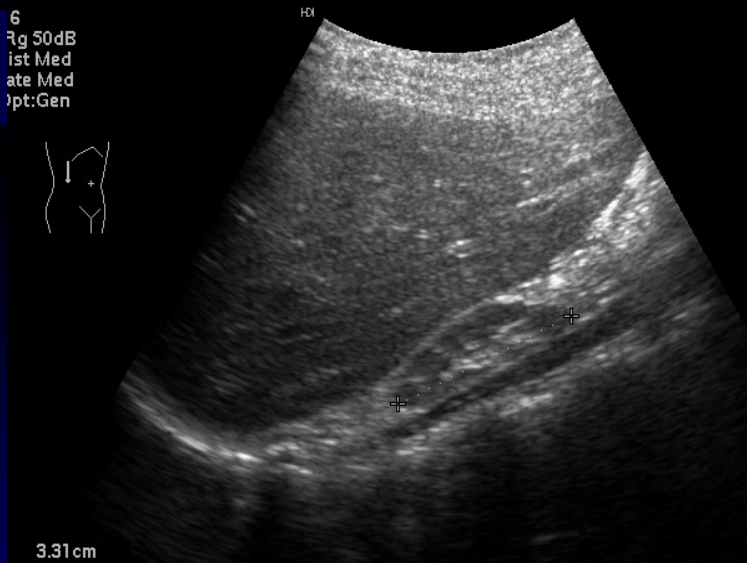

ECHOGENICITY OF KIDNEY NORMAL/ABNORMAL



SINGLE SMALL KIDNEY

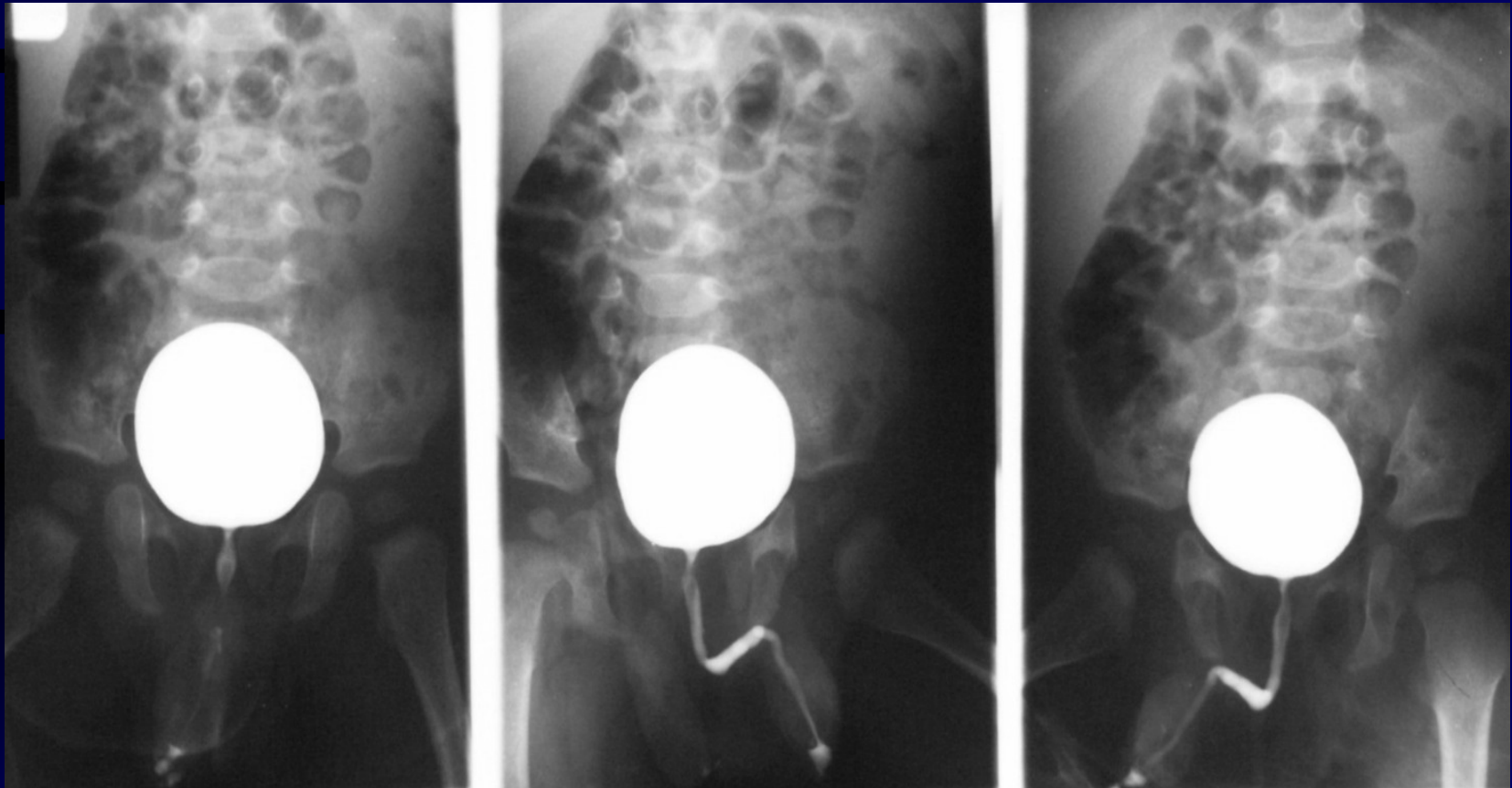
- **POST INFECTION NEPHROPATHY**
- CONGENITAL HYPOPLASTIC KIDNEY
- RENAL ARTERY STENOSIS
- RENAL VEIN THROMBOSIS



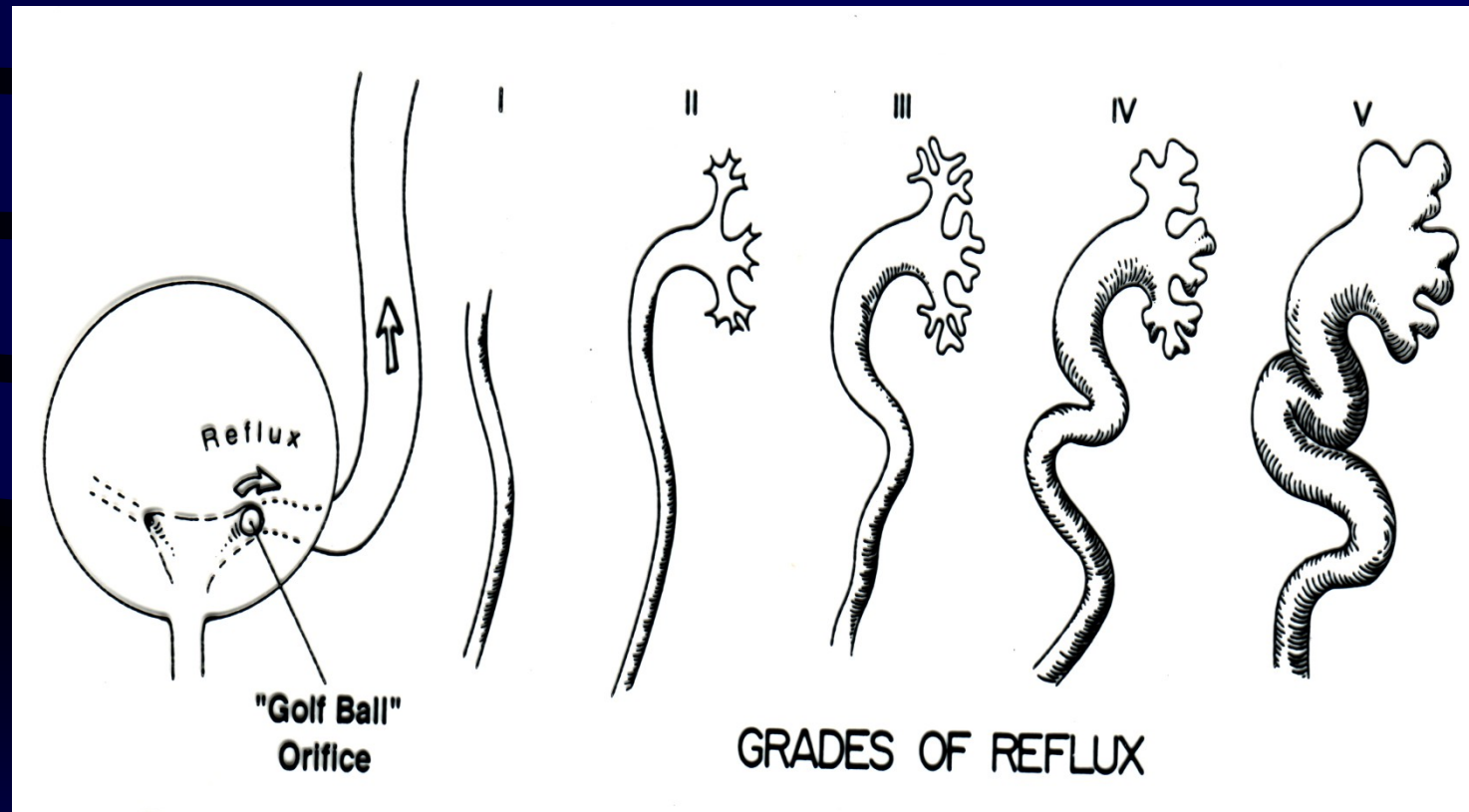
INDICATION FOR CYSTOURETHROGRAPHY /VCUG/

- URINARY TRACT INFECTION
- HYDRONEPHROSIS DETECTED
IN ULTRASOUNDS
- VOIDING DISFUNCTION

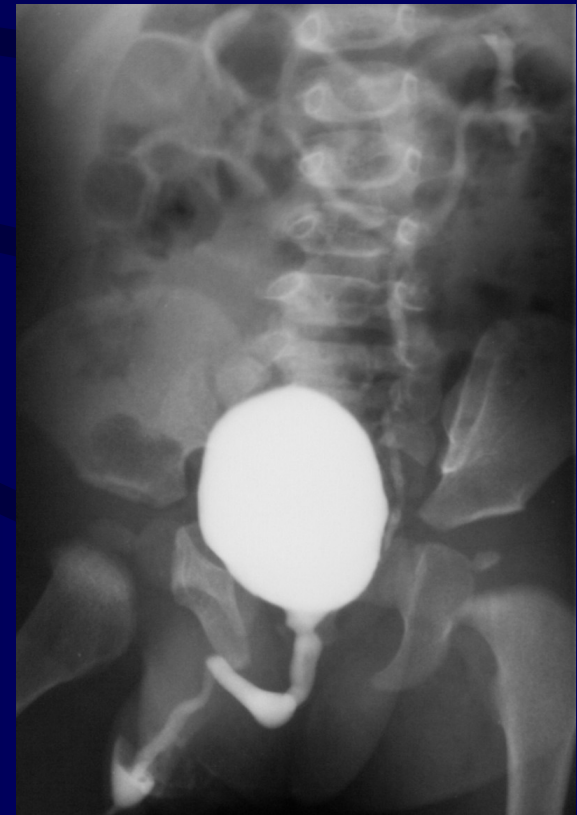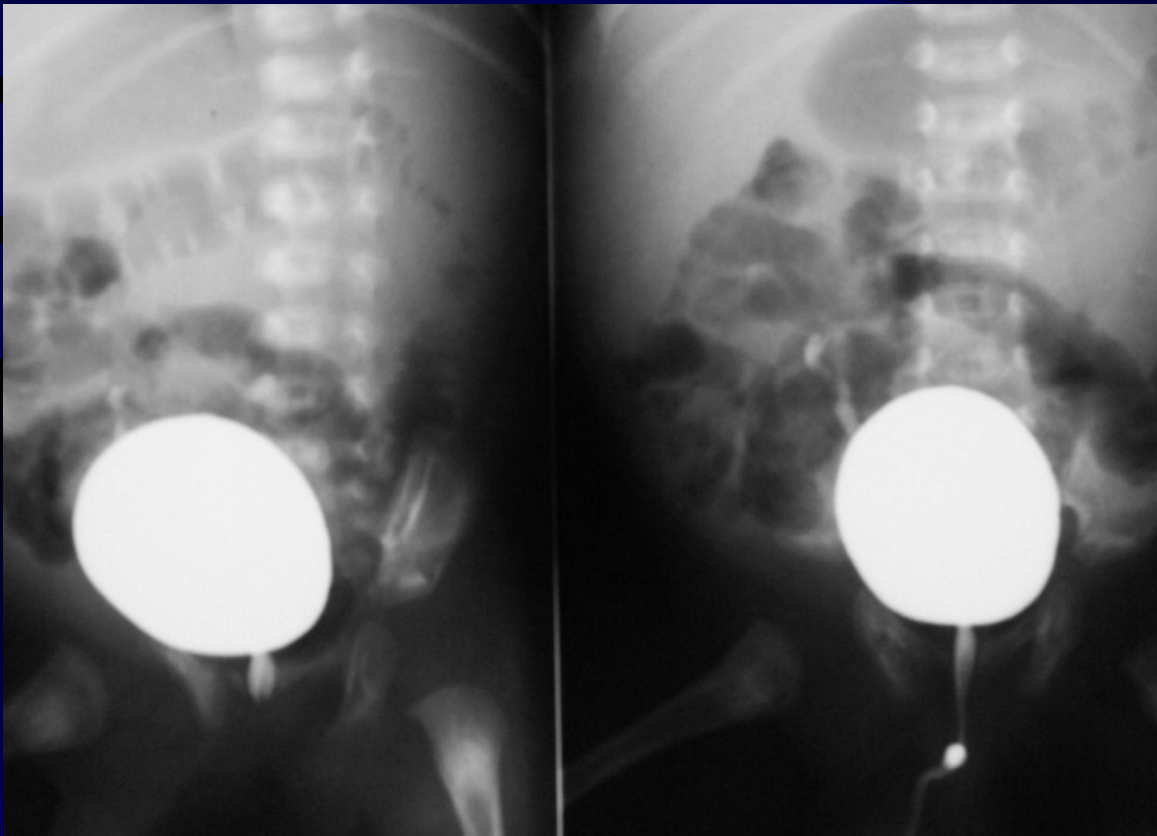
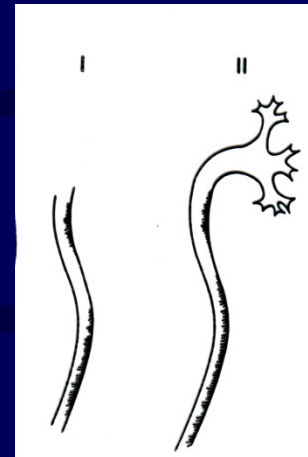
NORMAL VCUG



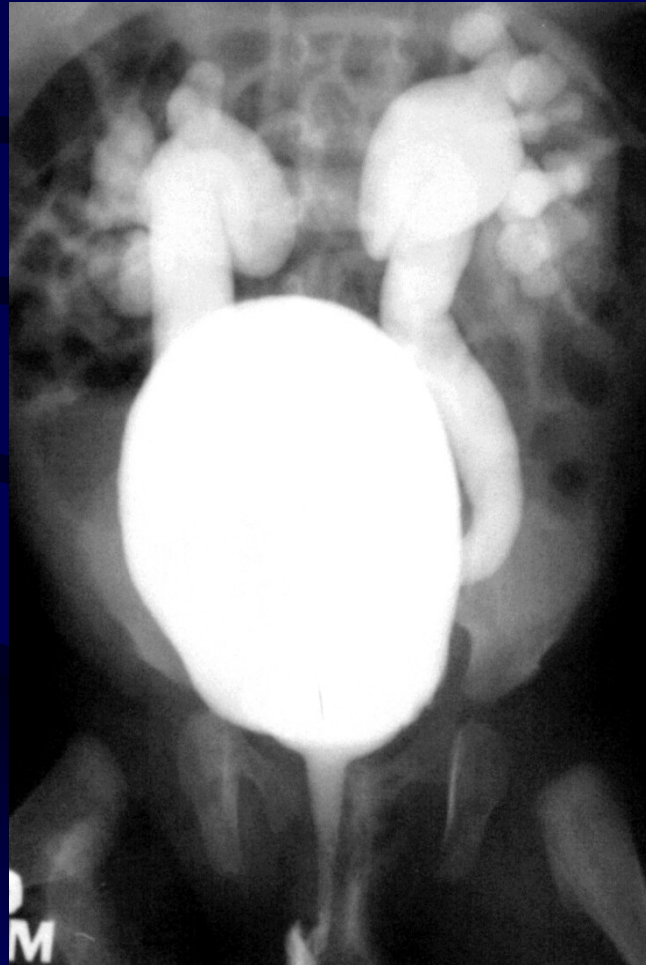
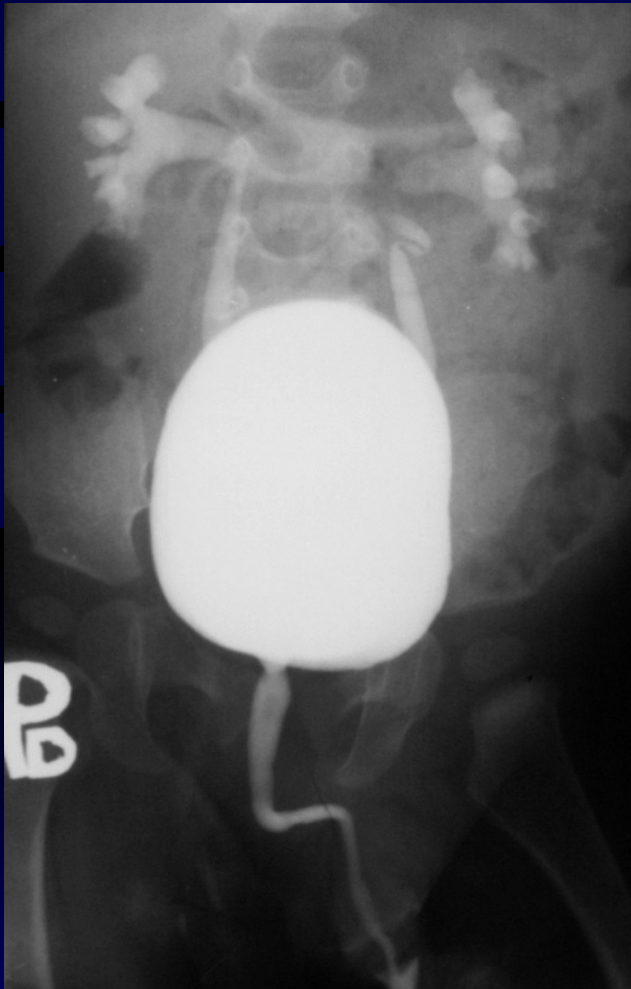
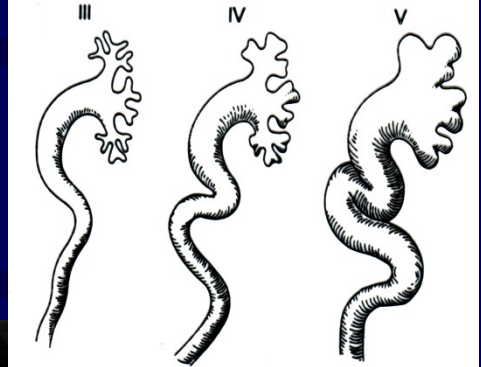
GRAIDING OF REFLUX



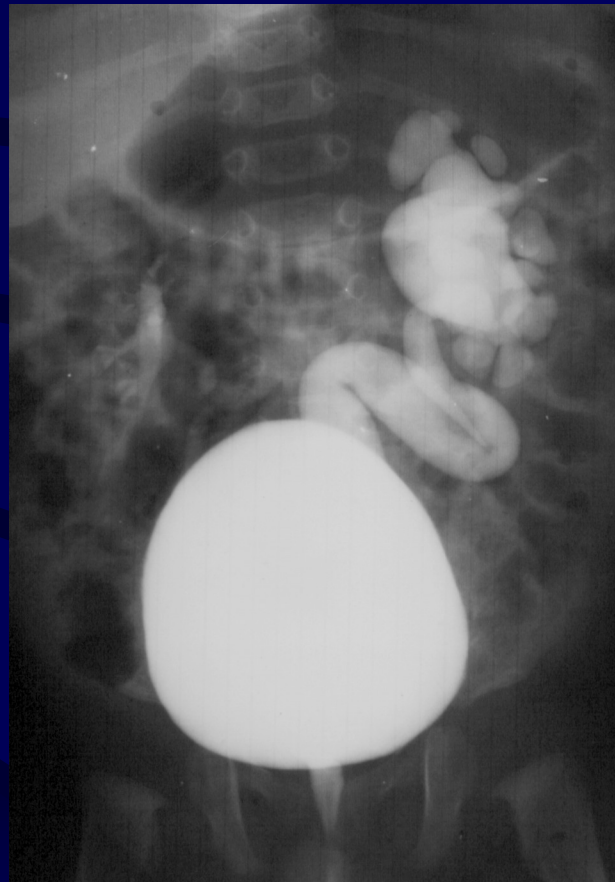
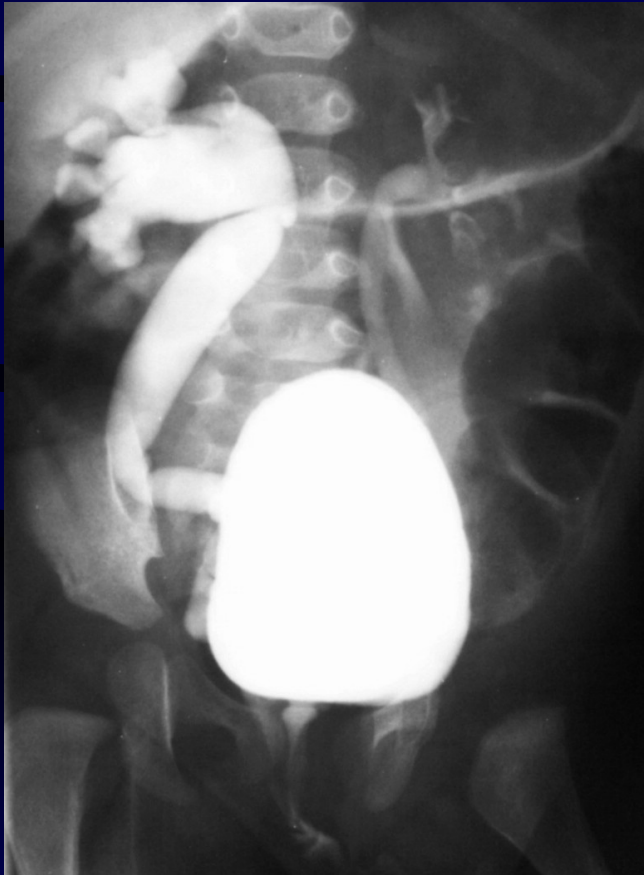REFLUX



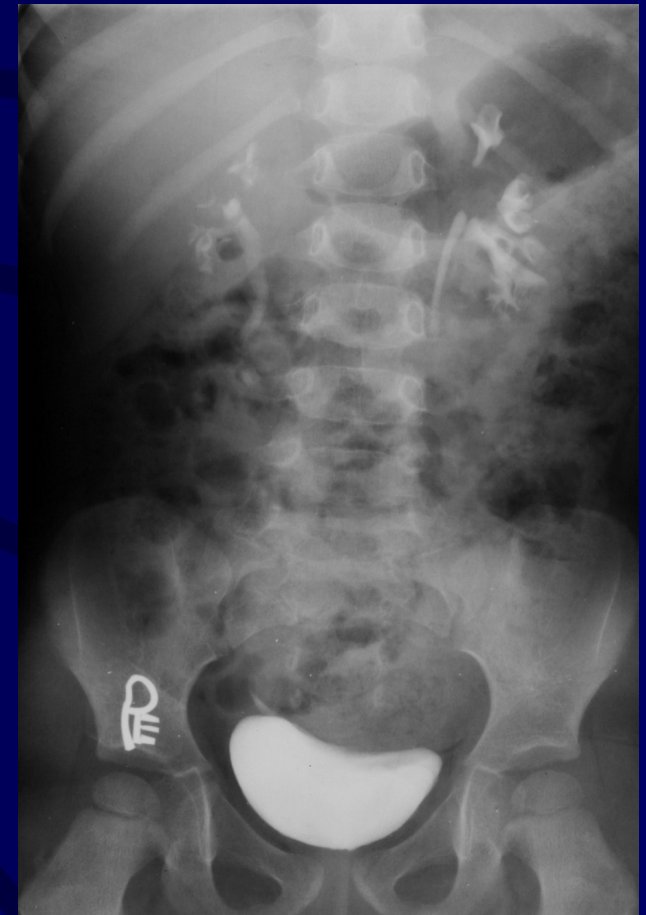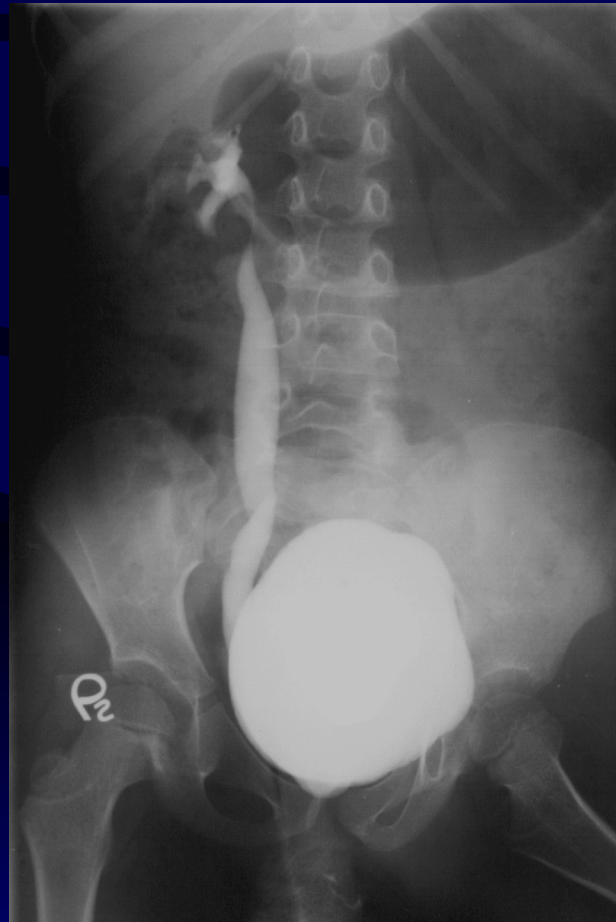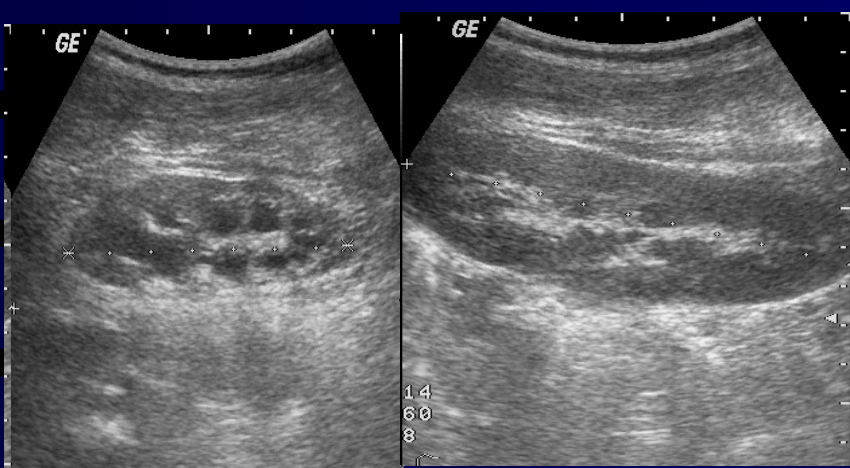
REFLUX



REFLUX



POST REFLUX NEPHROPATHY



INDICATIONS FOR IVP/UROCT

- ABNORMALITY IN US – HYDRONEPHROSIS
- TRAUMA OF URINARY TRACT
- SUSPECTED ECTOPIC URETER

CONTRAST MEDIA CLASSIFICATION

IODIC CM

SOLUBLE IN WATER

IONIC

UROPOLINUM

GASTROGRAFINUM

UROGRAFINUM

NONIONIC - AMIPAQ

OMNIPAQ

ULTRAVIST

CONTRAINDICATIONS FOR IVP/UROCT

- DEHYDRATATION
- SHOCK
- TOXIC GOITER
- MULTIPLE MYELOMA

CONTRAST MEDIA SIDE EFFECTS

- PHYSICO-BIOCHEMICAL SYMPTOMS ARE DEPENDENT ON DOSE AND HYPEROSMOLALITY
- ALLERGIC REACTIONS ARE NON DEPENDENT ON THE DOSE OF CONTRAST MEDIA

SIDE EFFECTS AFTER CONTRAST MEDIA

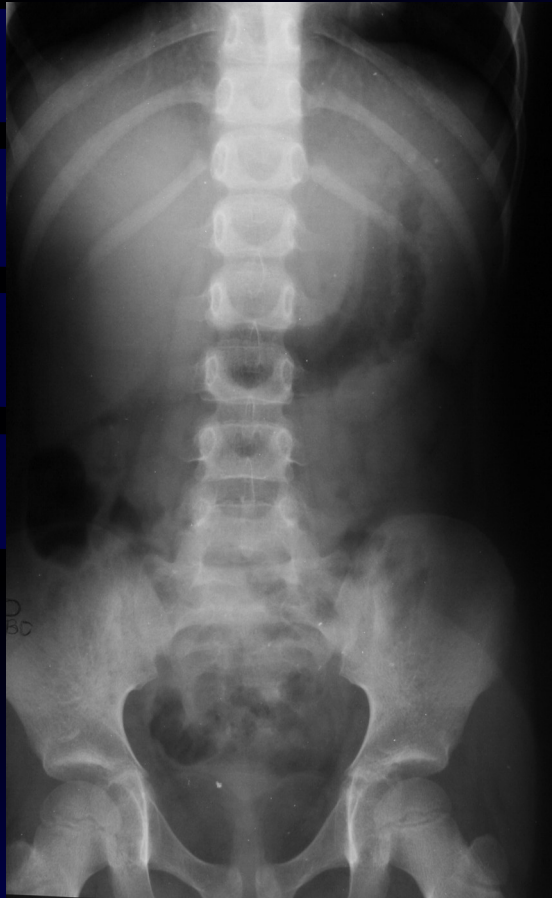- ALLERGY –LIKE REACTIONS

- ANAPHYLACTIC SHOCK
- GENERALIZED PRURITUS
- SNEESING
- COUGHING

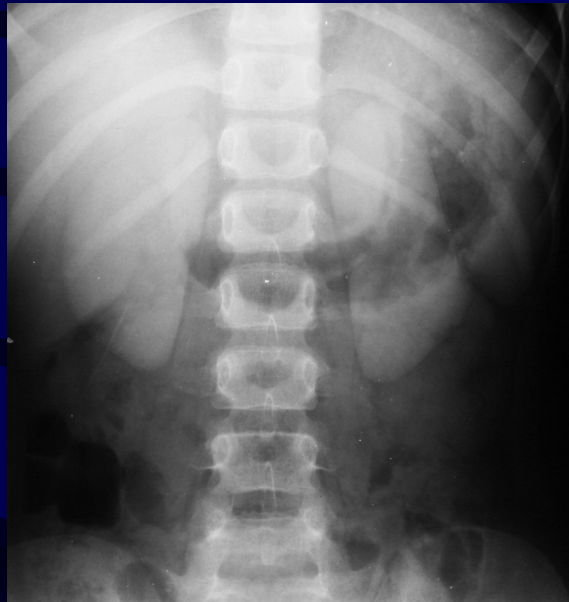
- NON- ALLERGIC REACTION

- DECREASE IN BLOOD PRESSURE
- VASODILATATION
- PAIN SENSATION
- HEAT SENSATION

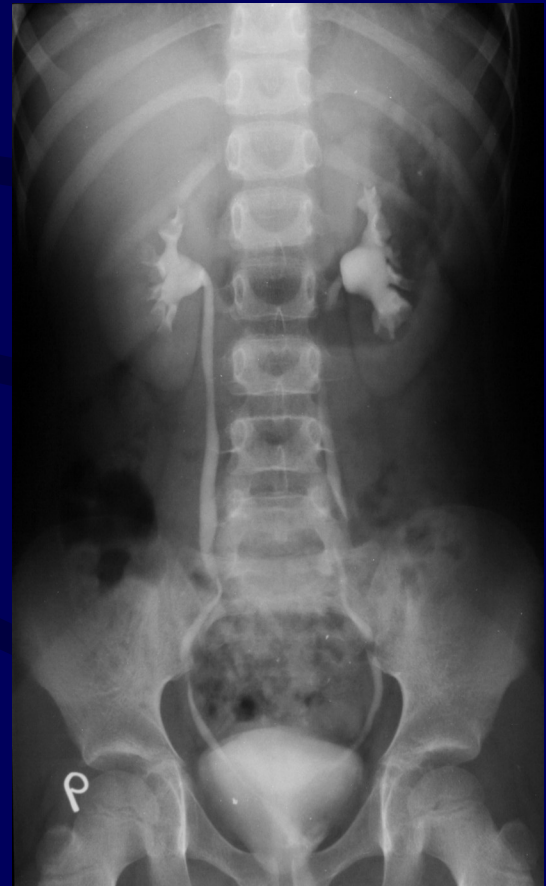NORMAL IVP



PLAIN FILM

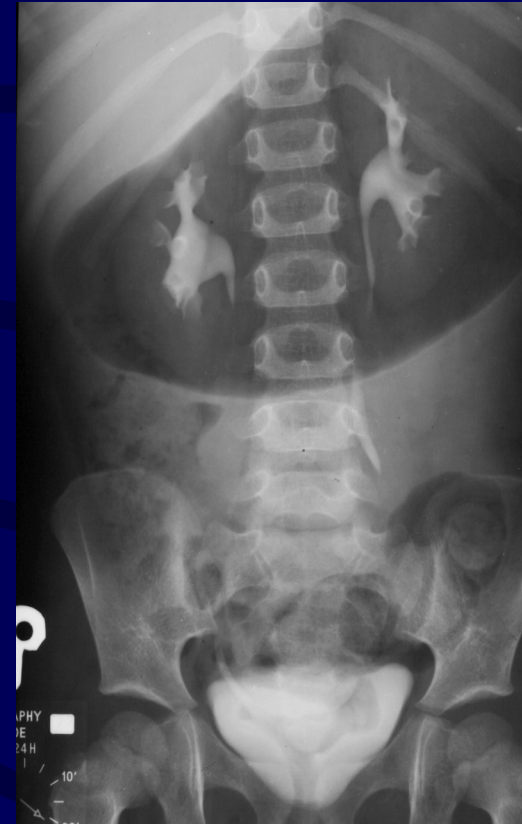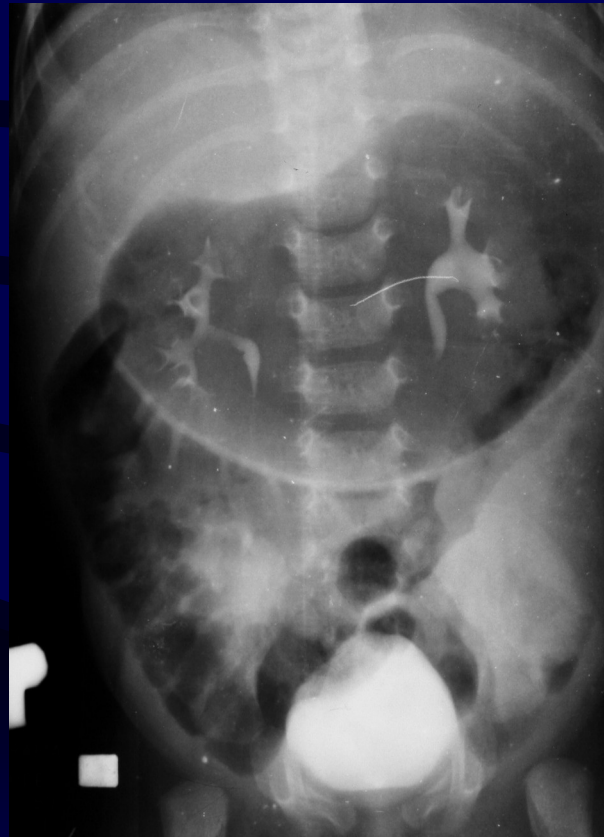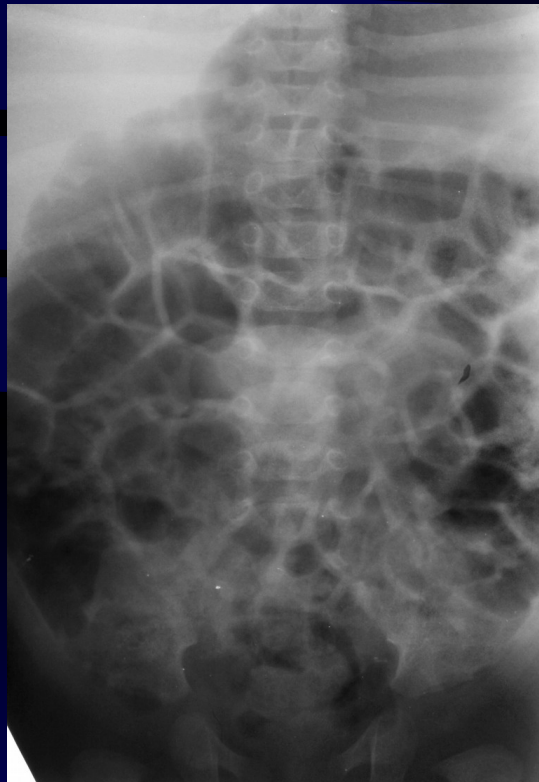


1 MIN.

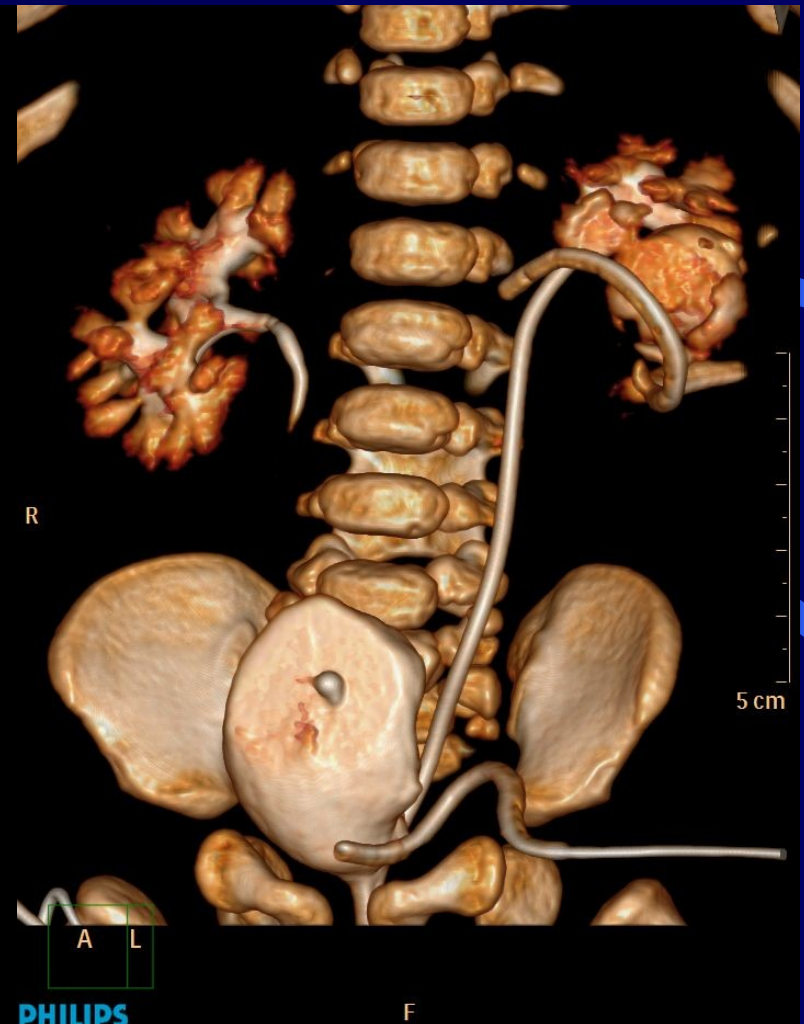
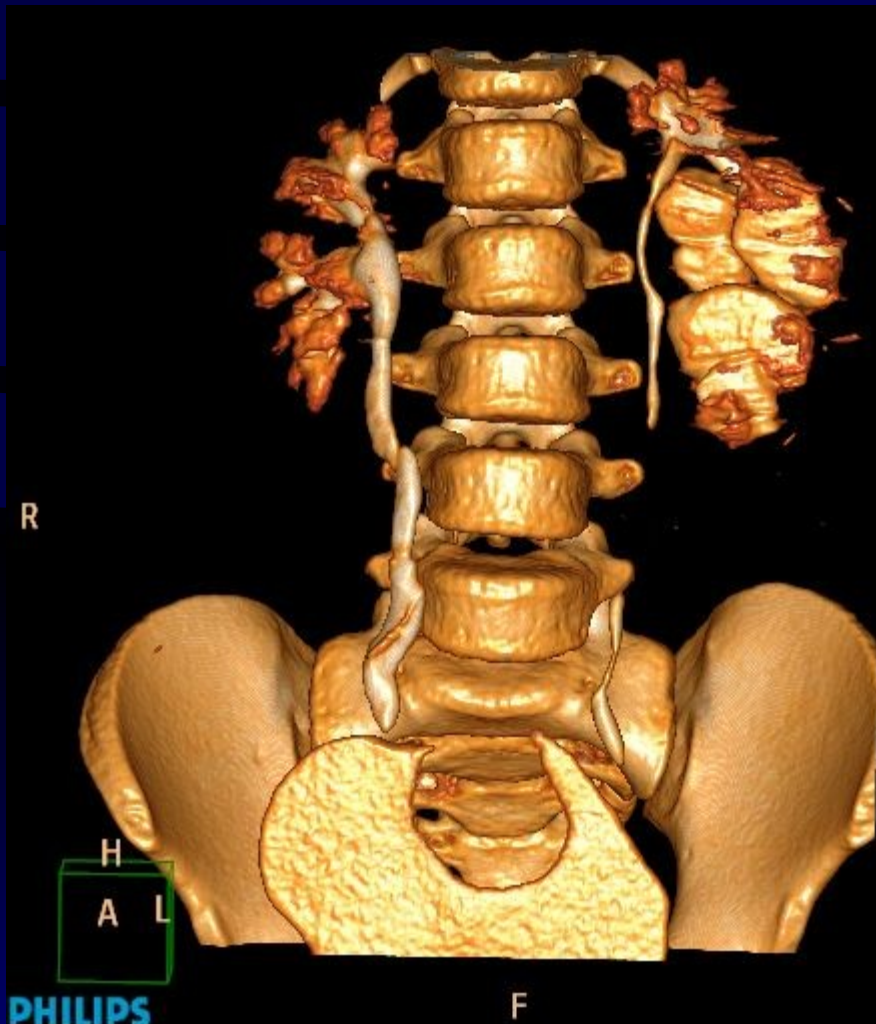


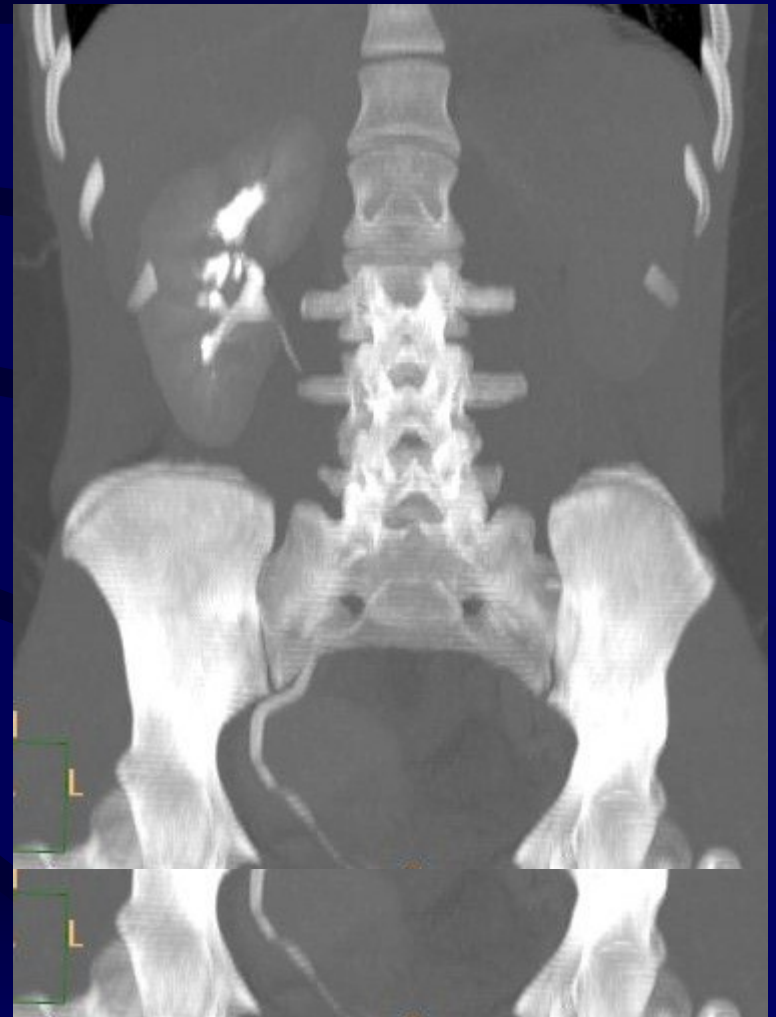
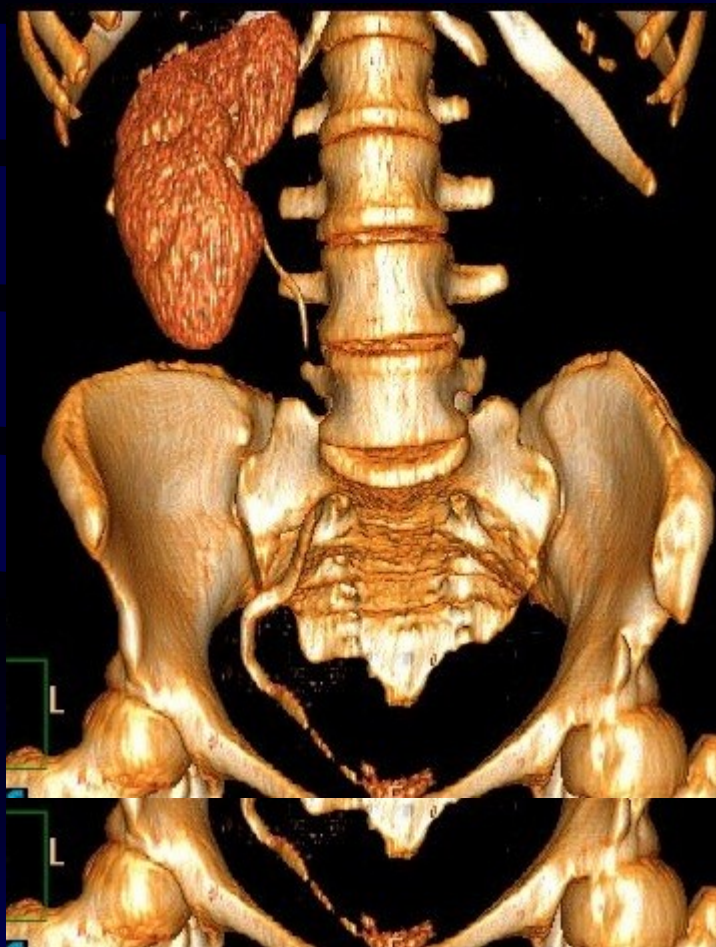
15 MIN.

INFANT IVP



URO-CT

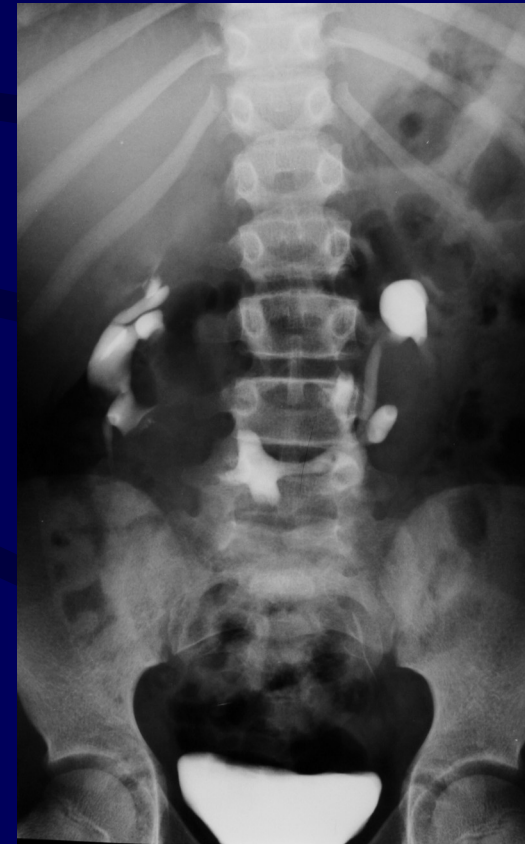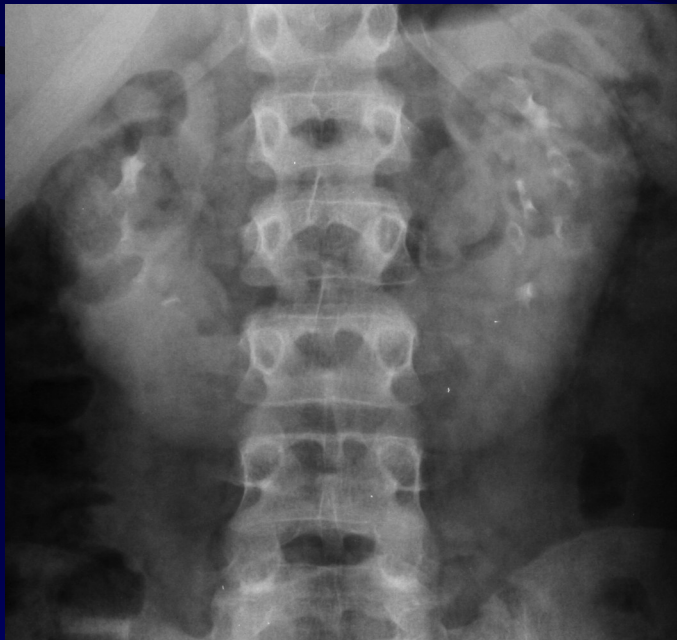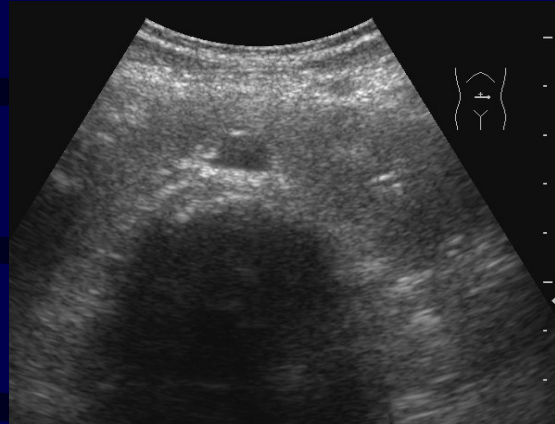


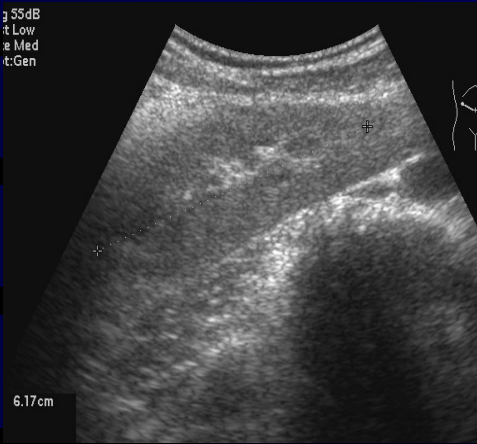

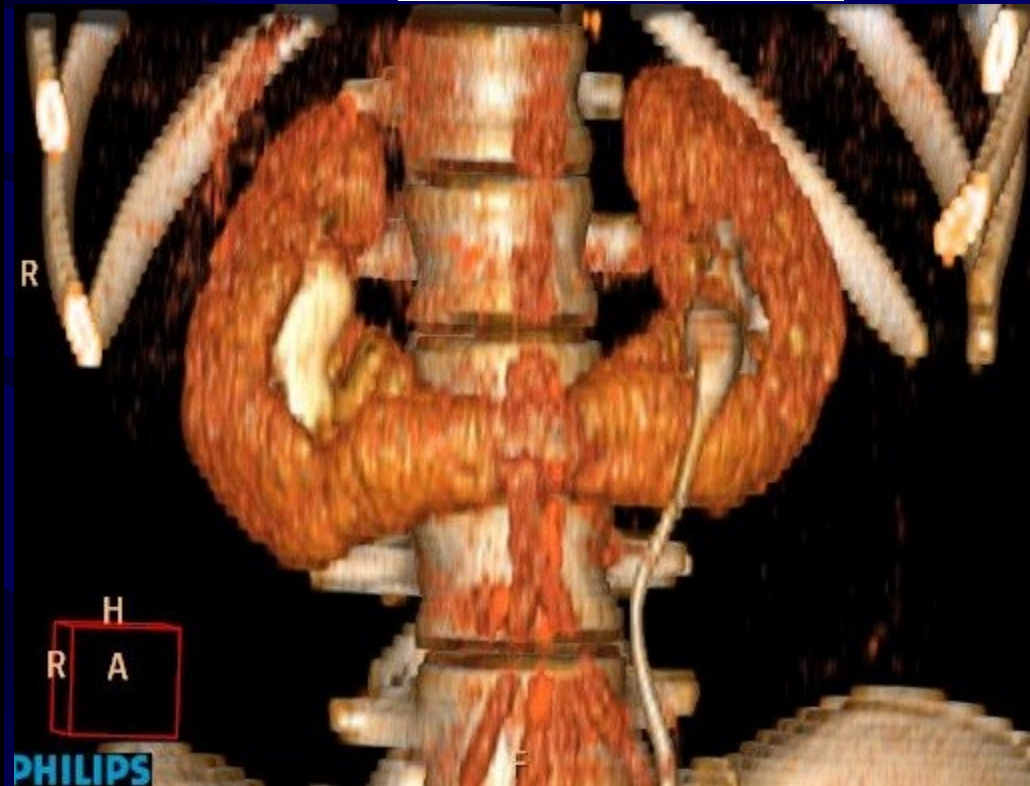
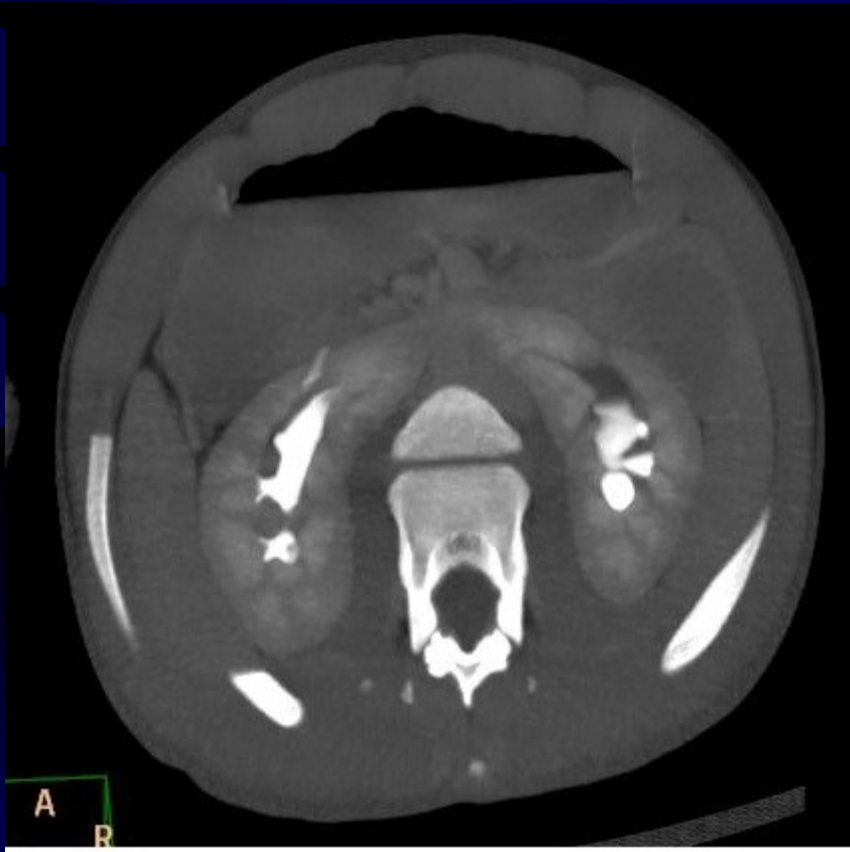
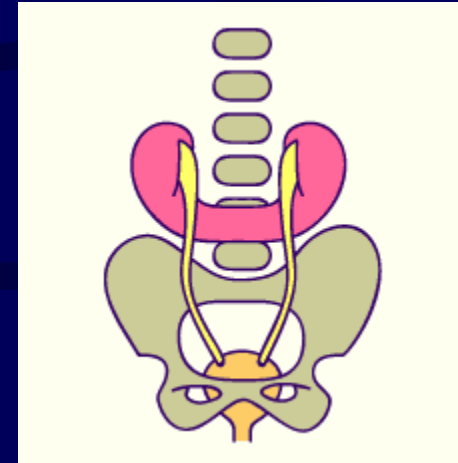
CONGENITAL URINARY TRACT ANOMALIES

- **RENAL AGENESIS**
- **RENAL HYPOPLASIA**
- **RENAL ECTOPIA**
- **DUPLEX COLLECTING SYSTEM**
- **ECTOPIC URETER**
- **MULTICYSTIC DYSPLASTIC KIDNEY**
- **HYDRONEPHROSIS**
 - **URETERO-PELVIC JUNCTION OBSTRUCTION**
 - **URETERO-VESICAL JUNCTION OBSTRUCTION**
 - **POSTERIOR URETHRAL VALVE**
 - **URETEROCELE /SIMPLEX, ECTOPIC/**

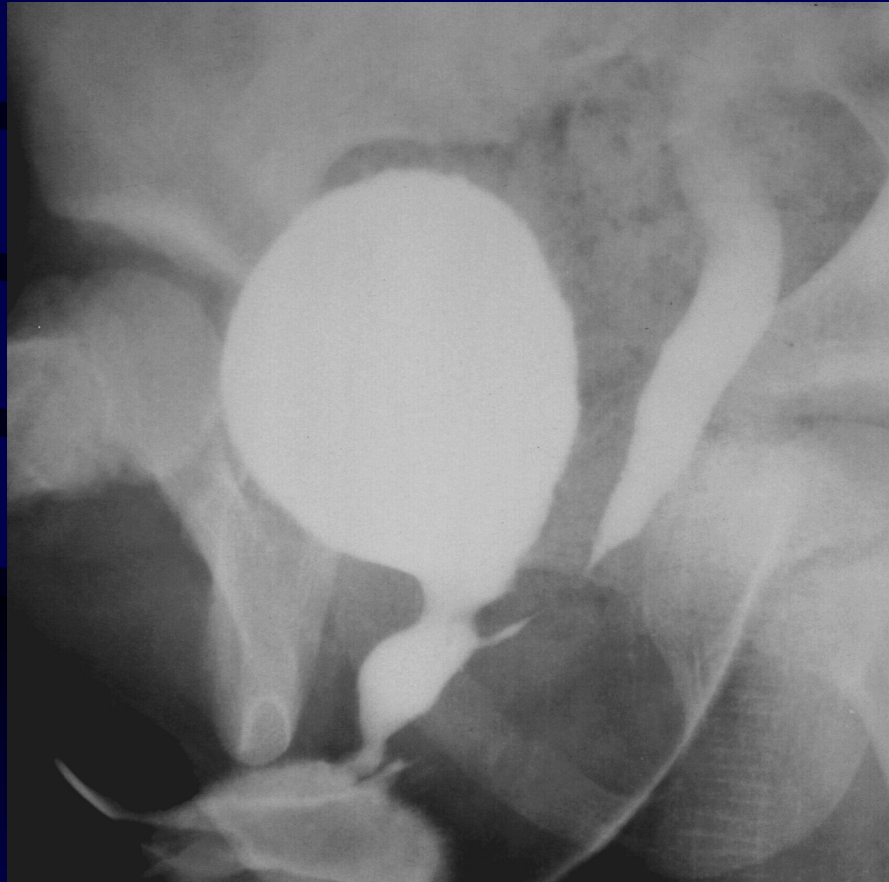HORSESHOE KIDNEY



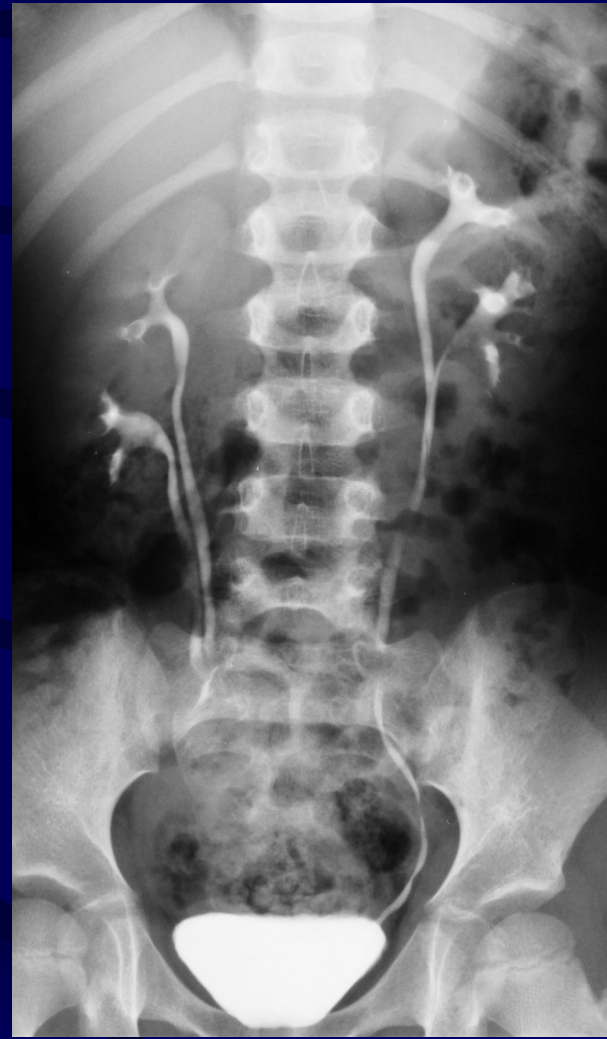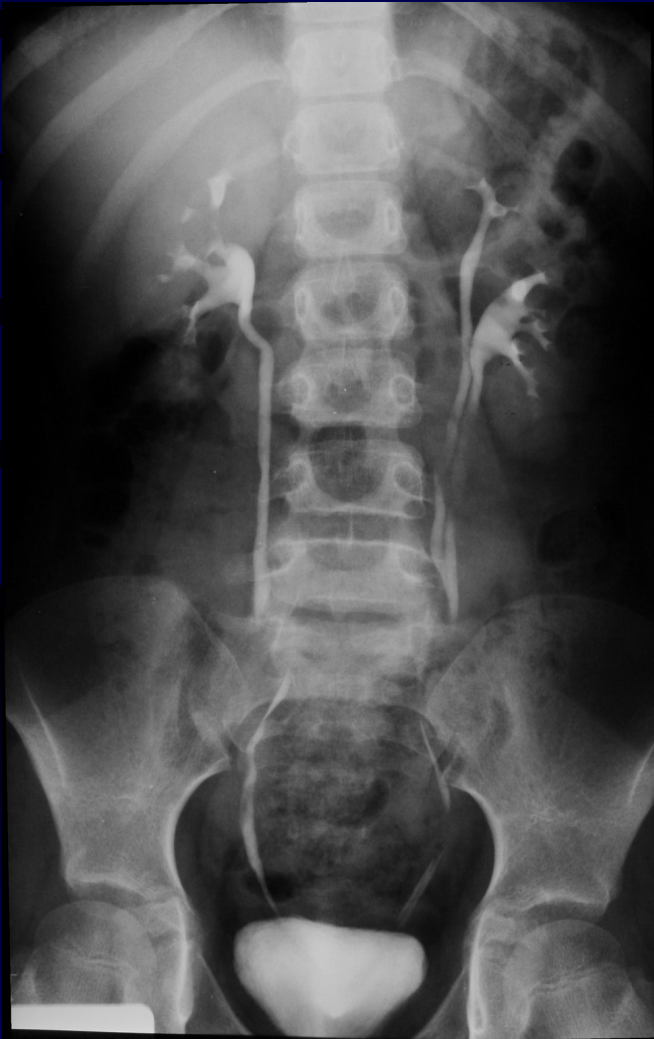HORSESHOE KIDNEY



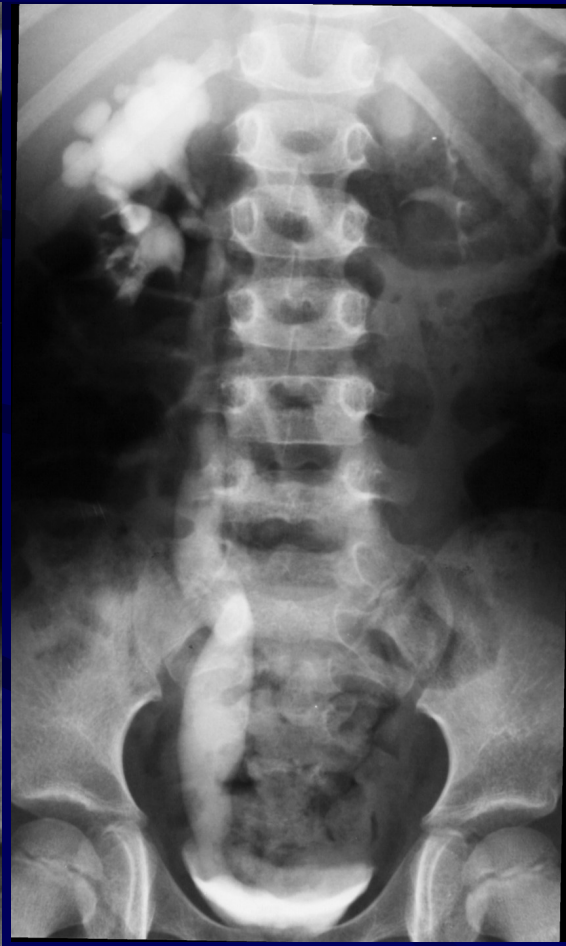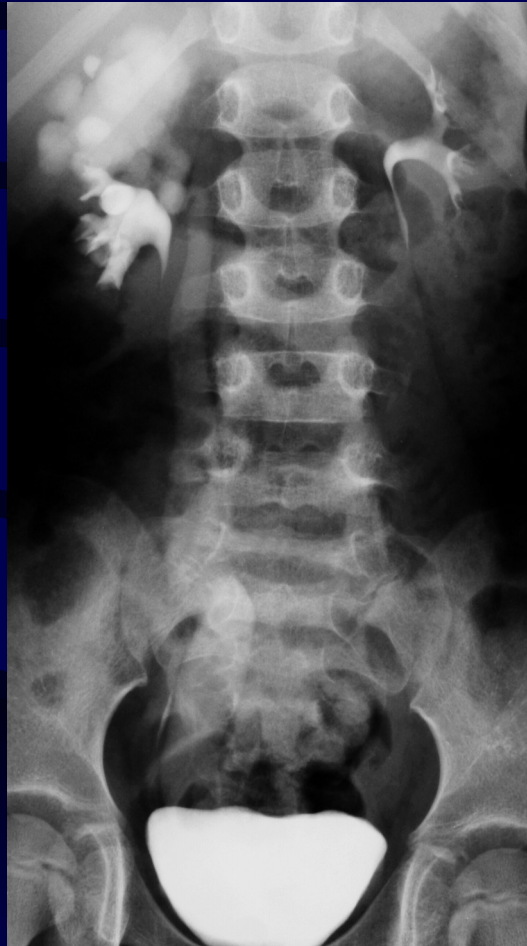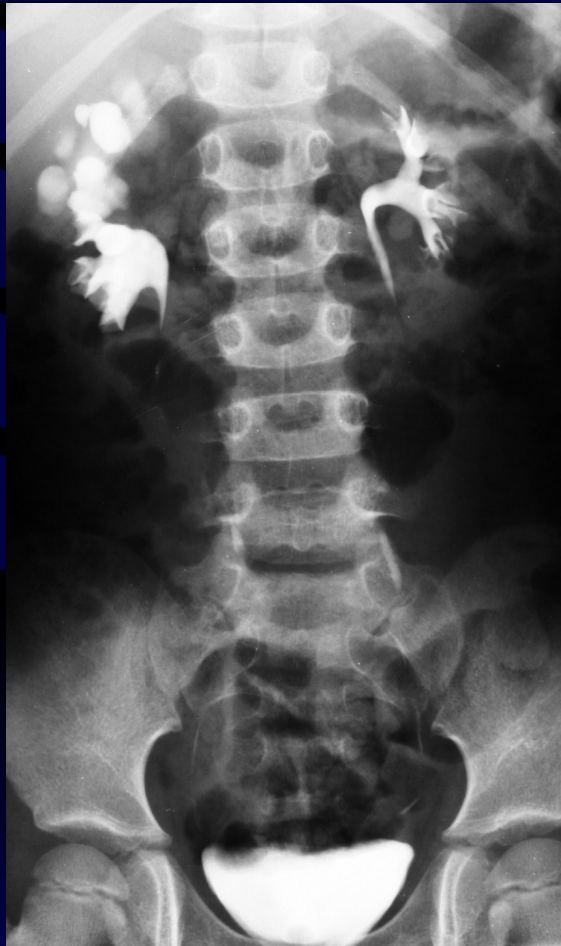ECTOPIC URETER



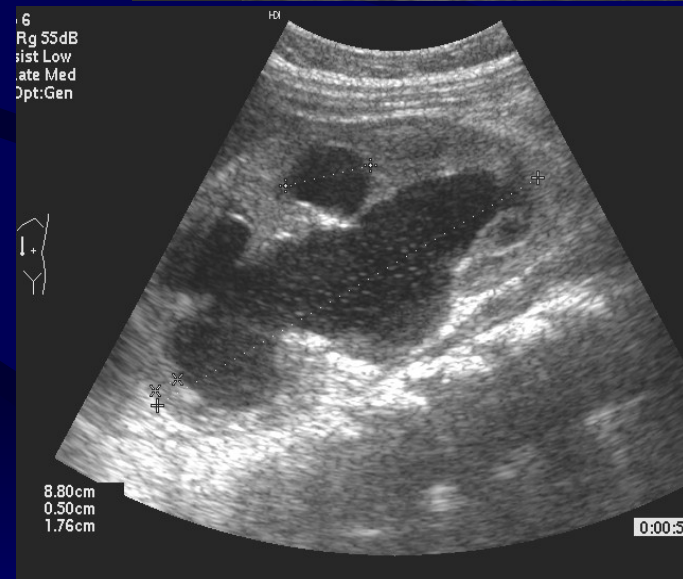
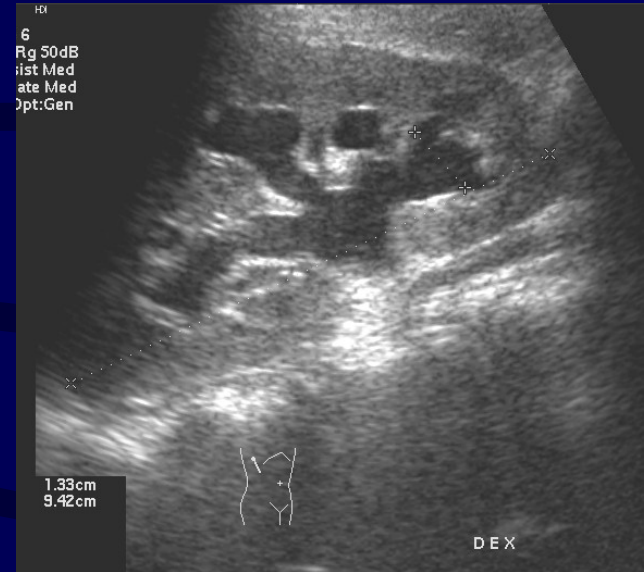
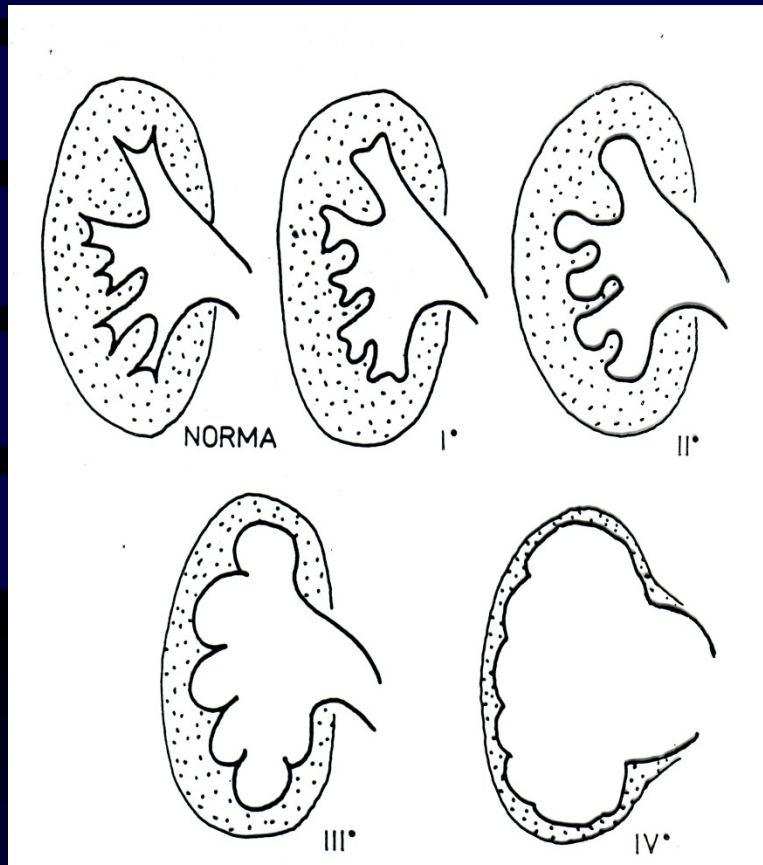
DUPLEX COLLECTING SYSTEM



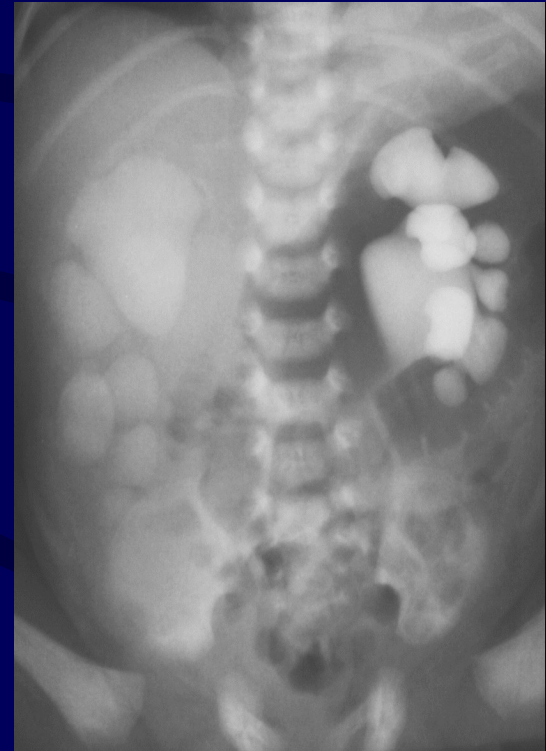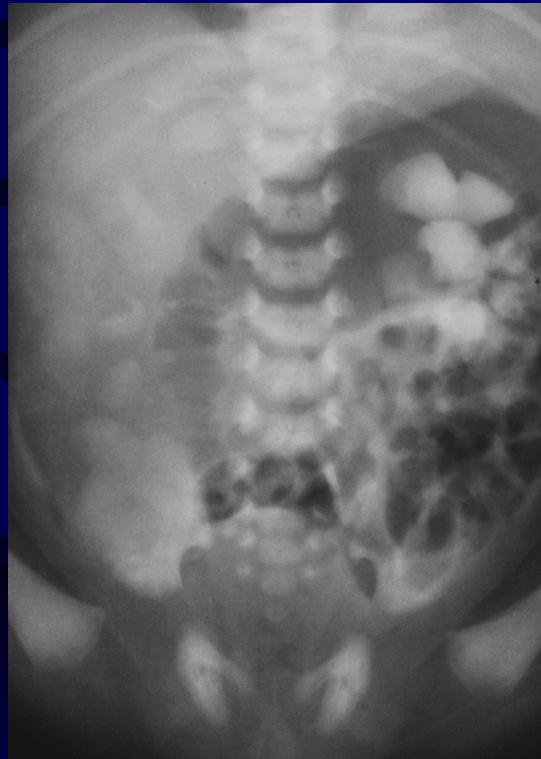
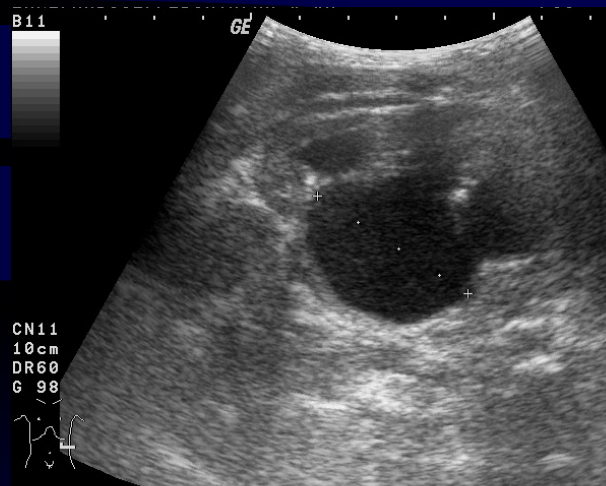
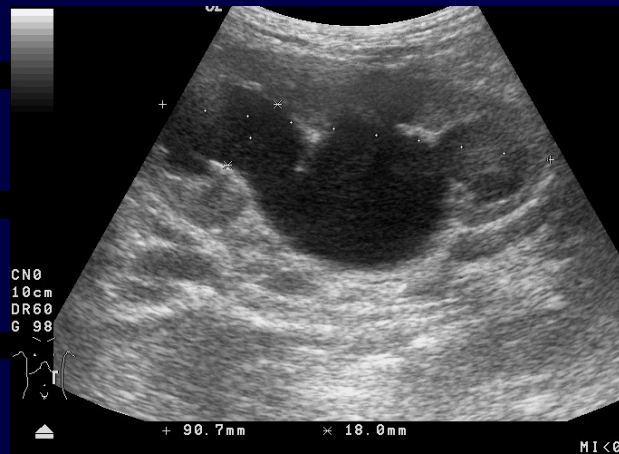ECTOPIC URETER



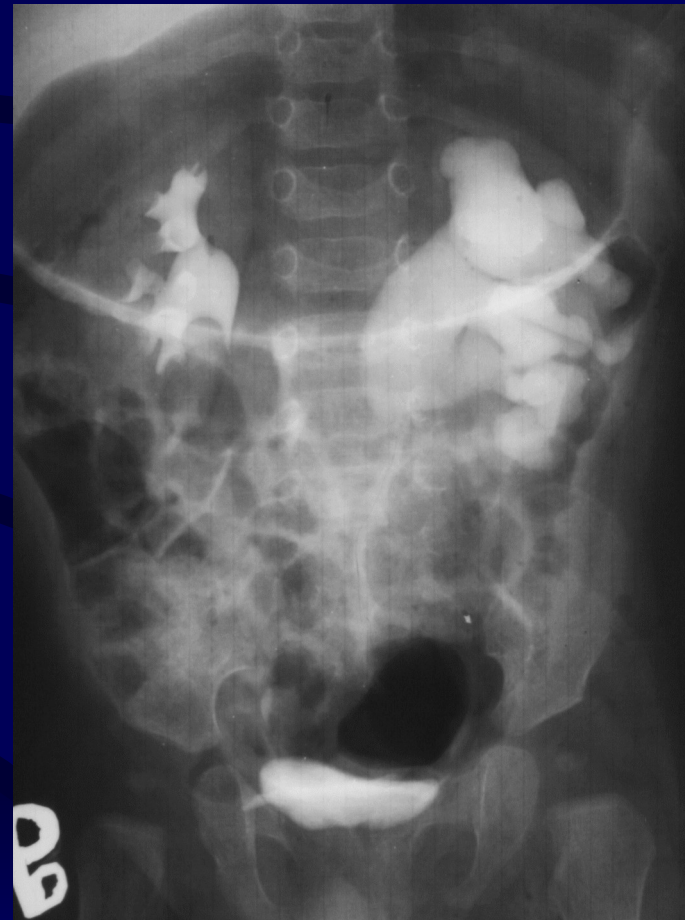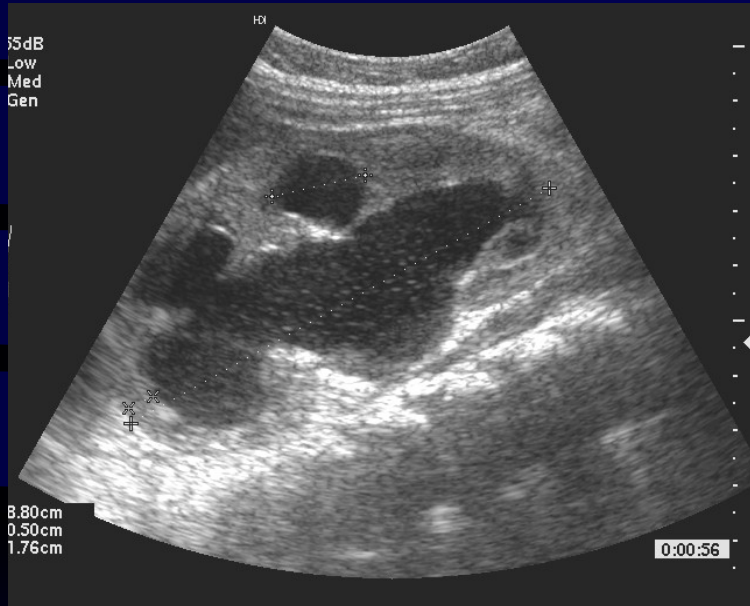HYDRONEPHROSIS



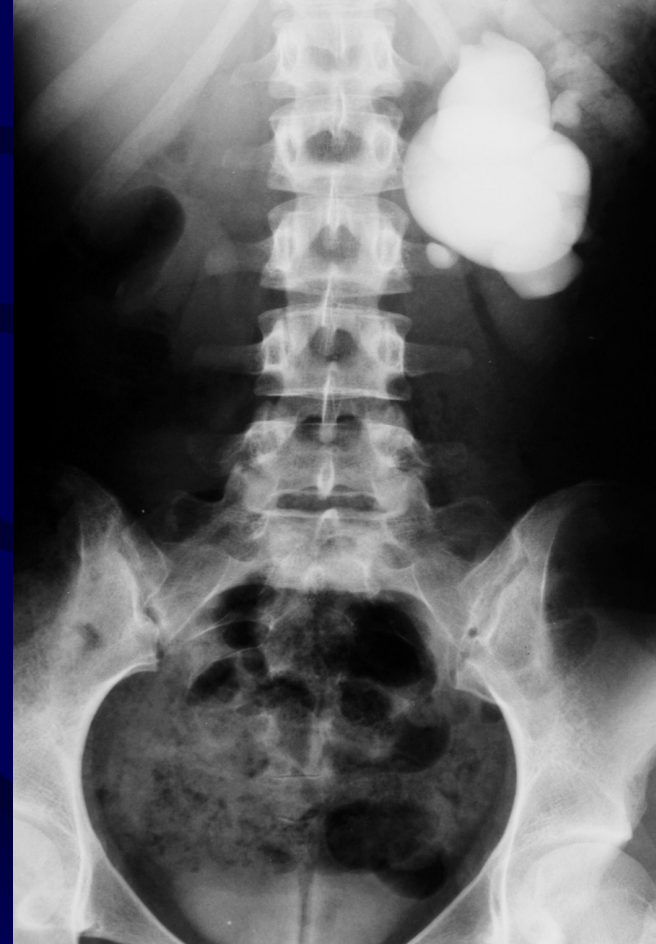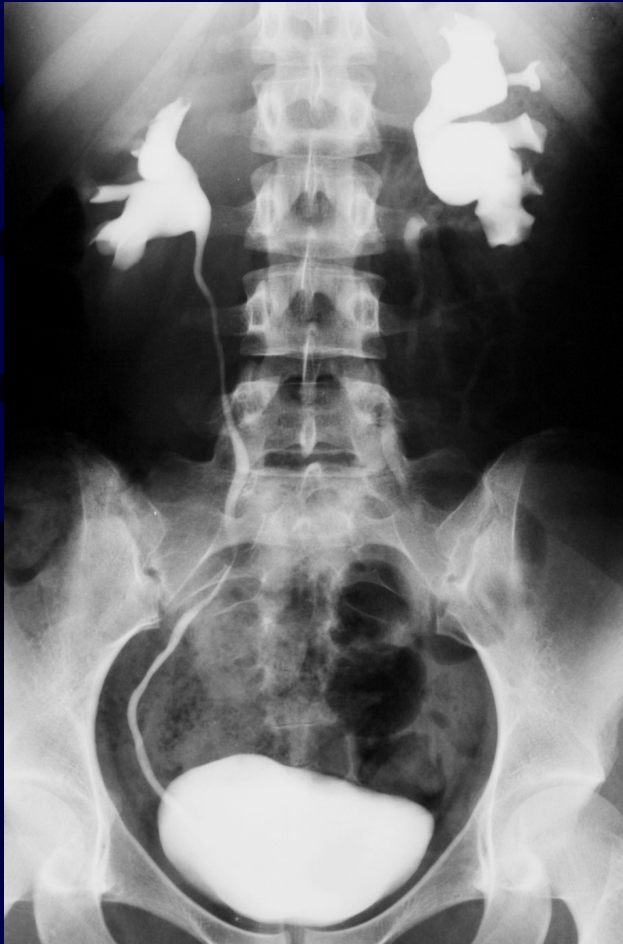URETERO-PELVIC JUNCTION OBSTRUCTION



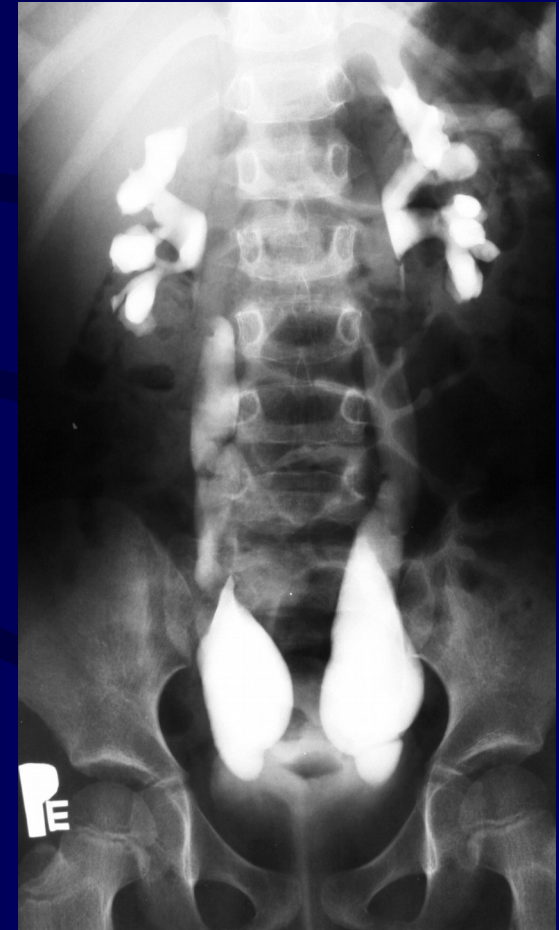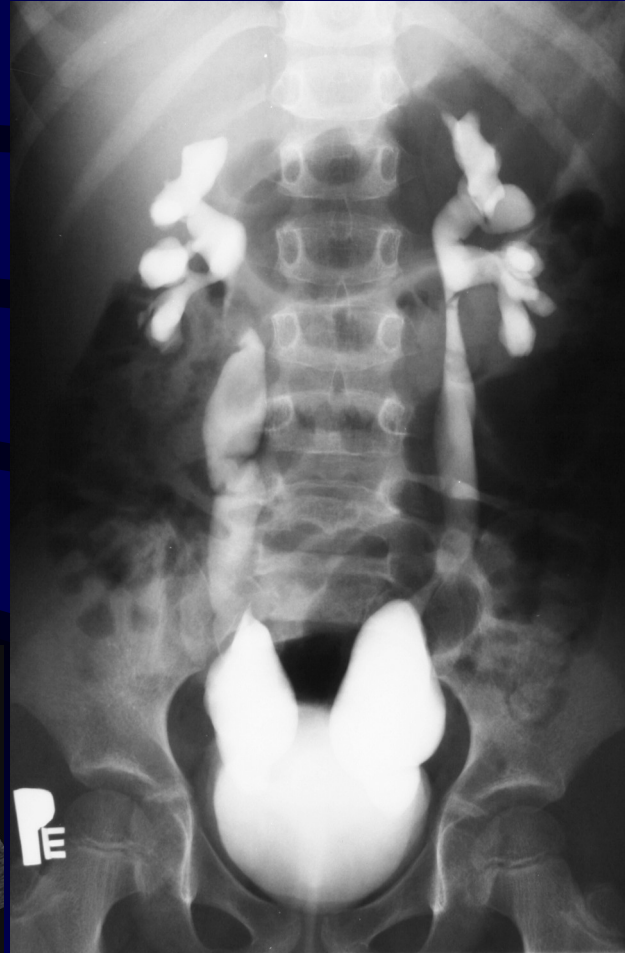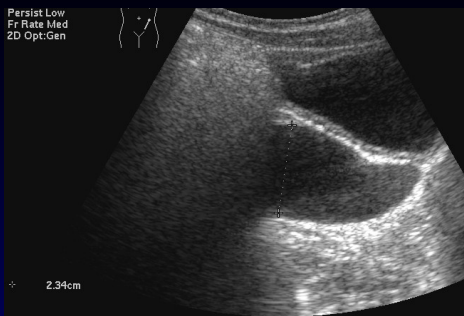
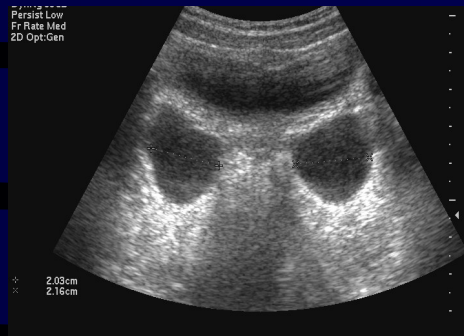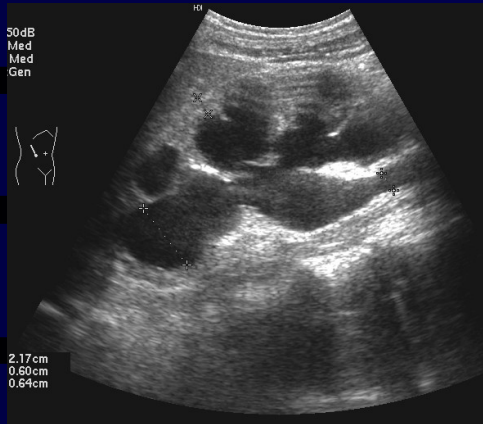URETERO-PELVIC JUNCTION OBSTRUCTION



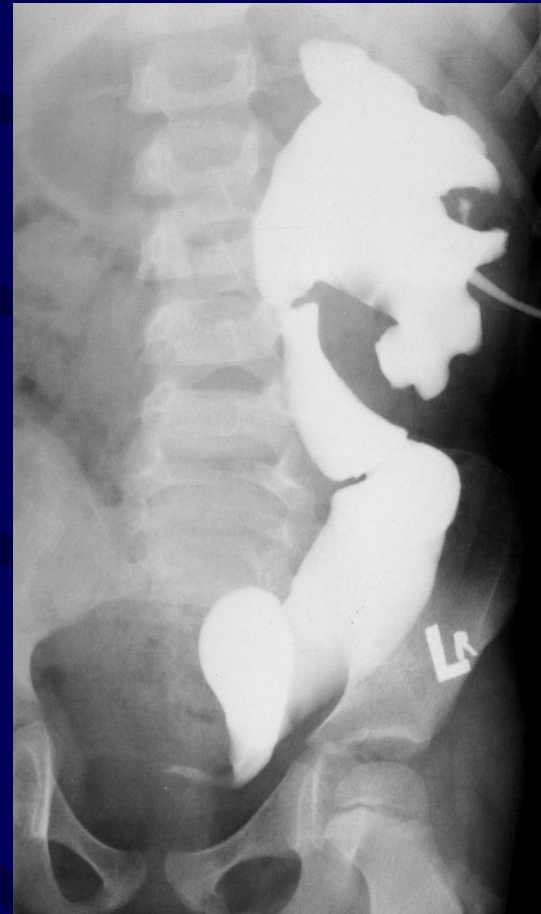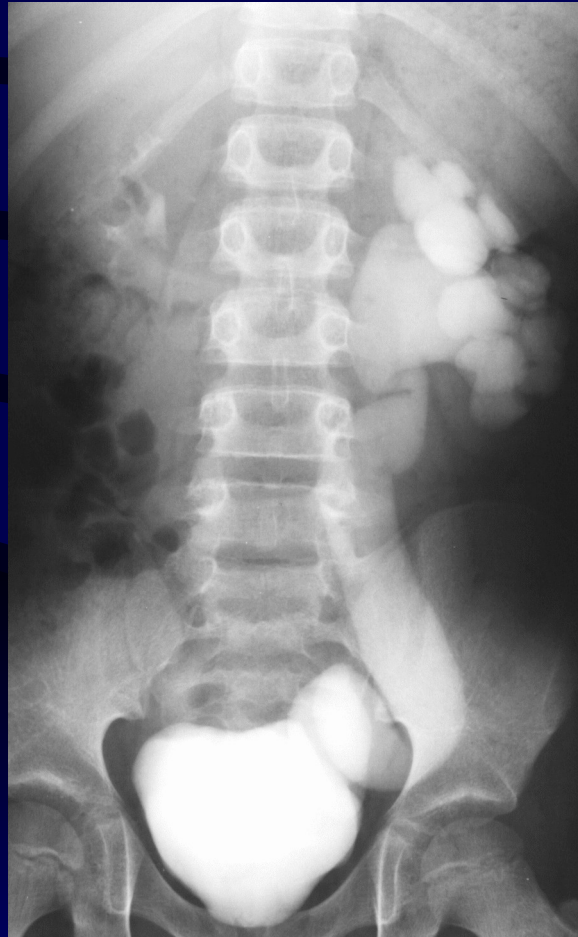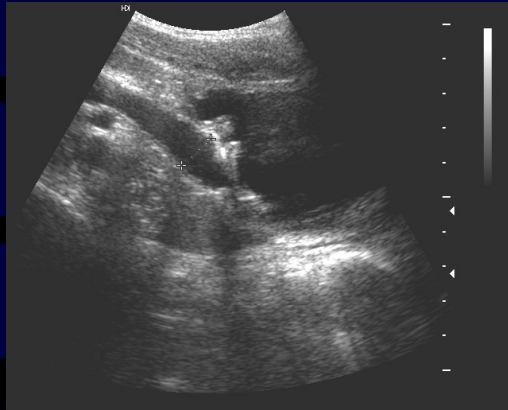
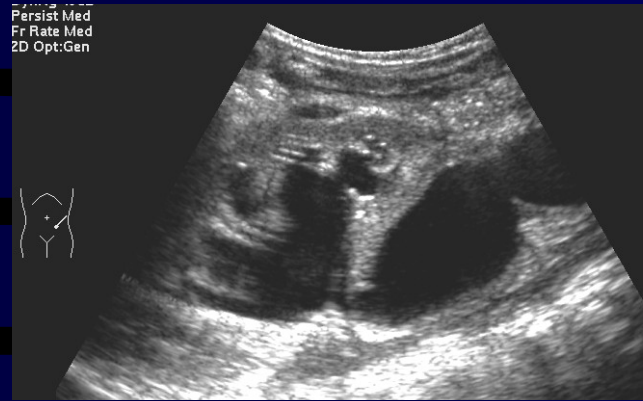
HYDRONEPHROSIS - FUROSEMIDE



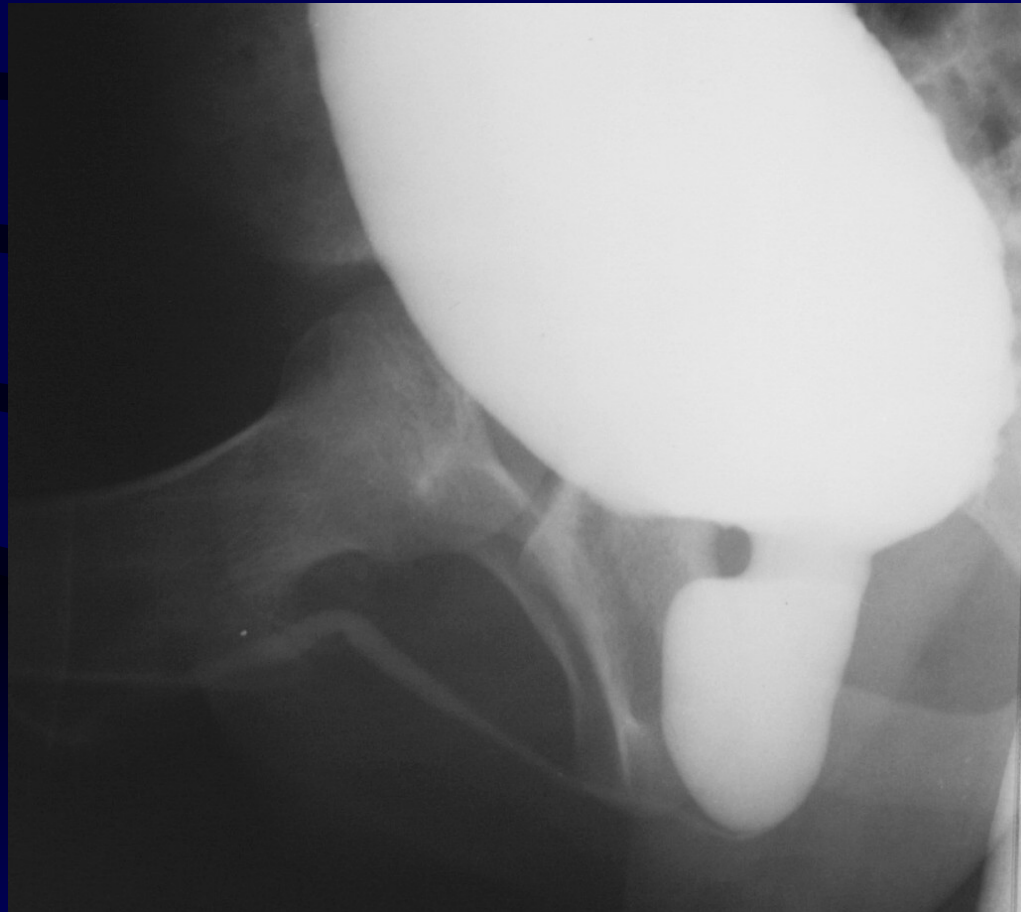
URETERO-VESICAL JUNCTION OBSTRUCTION



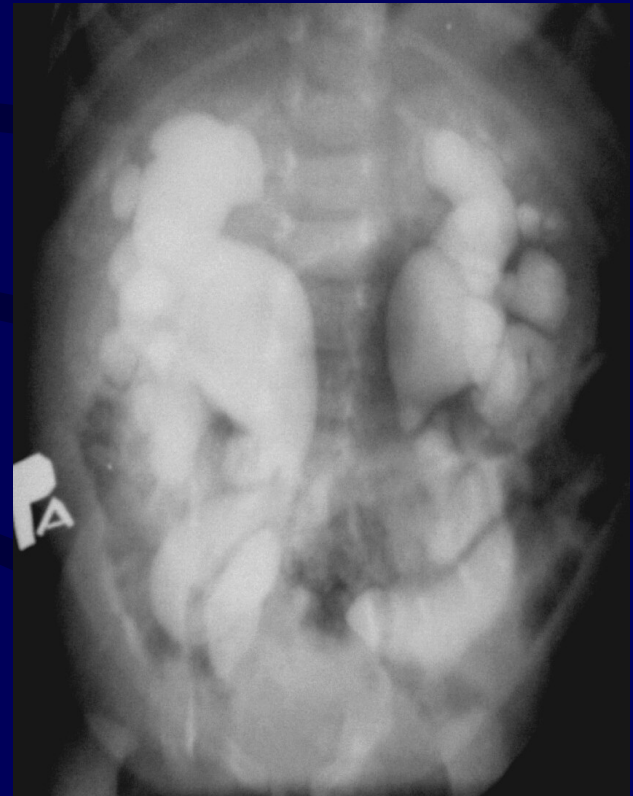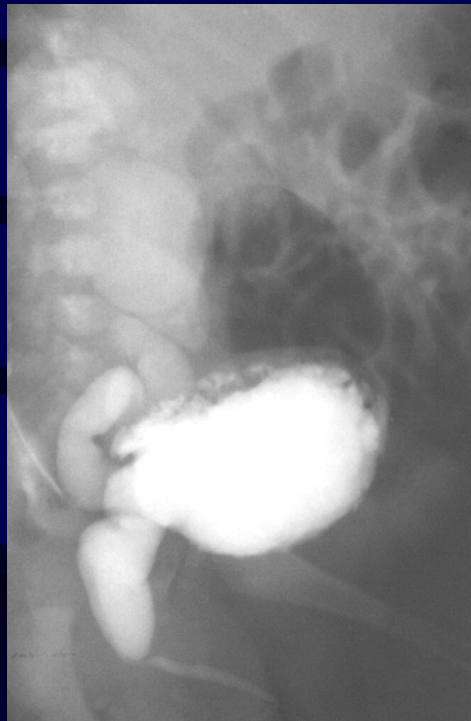
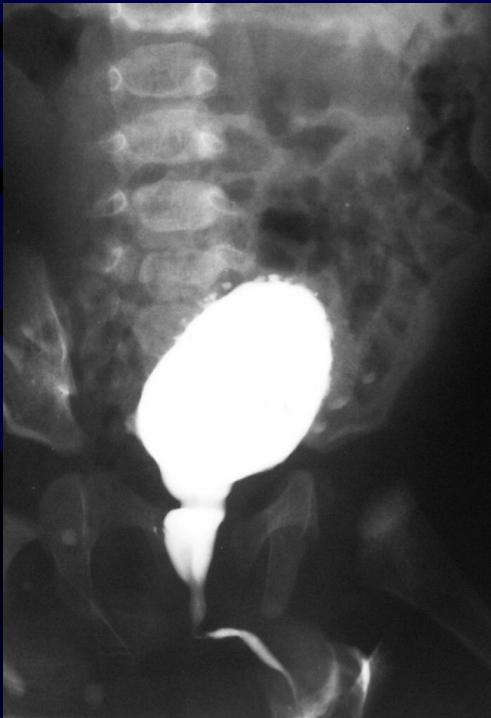URETERO-VESICAL JUNCTION OBSTRUCTION



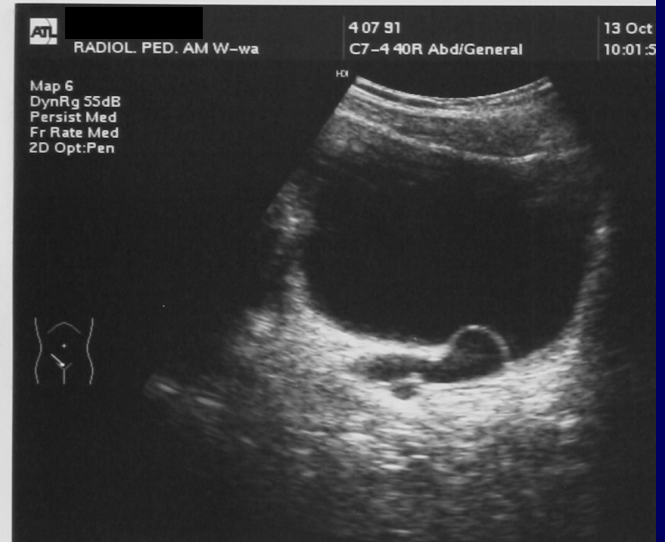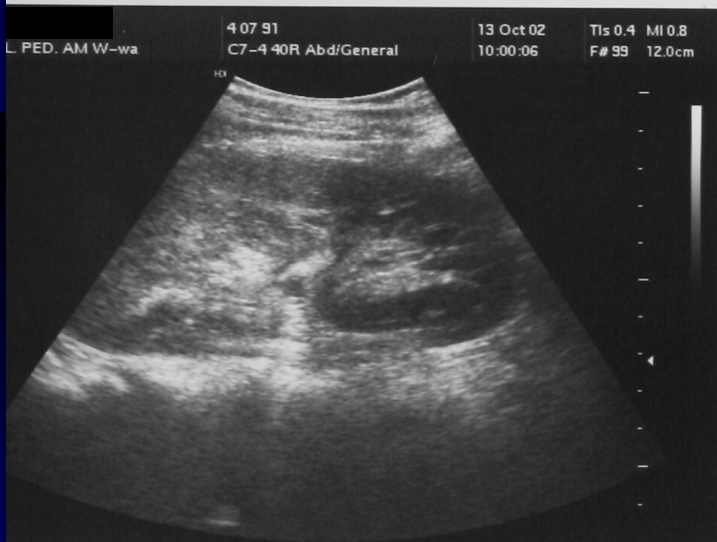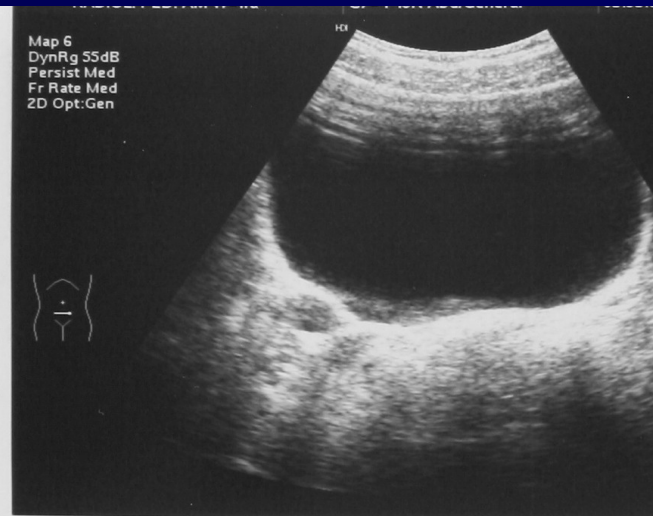
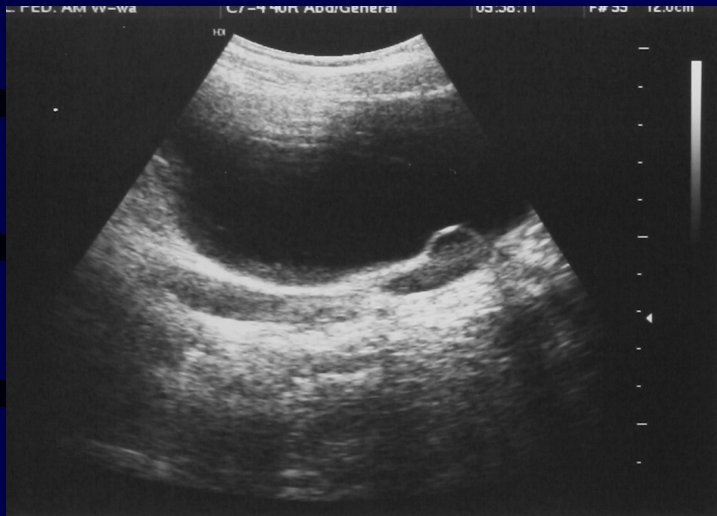
POSTERIOR URETHRAL VALVE



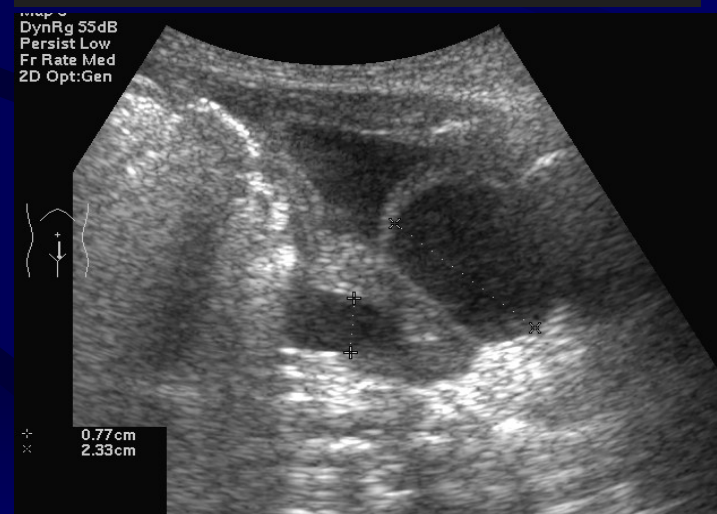
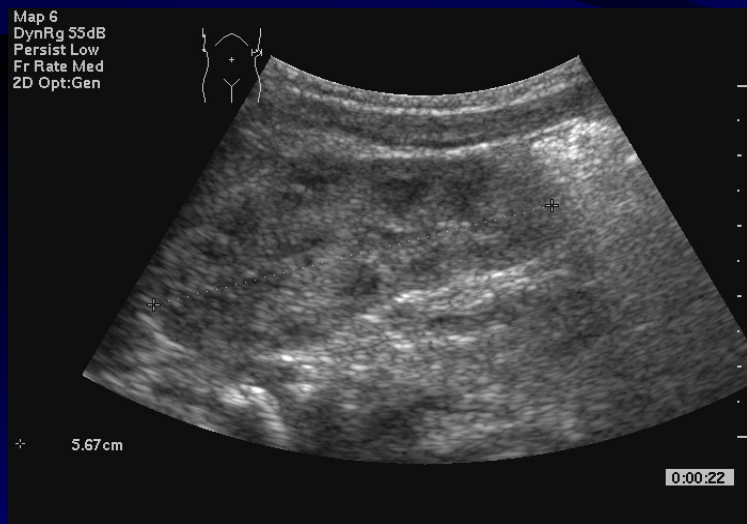
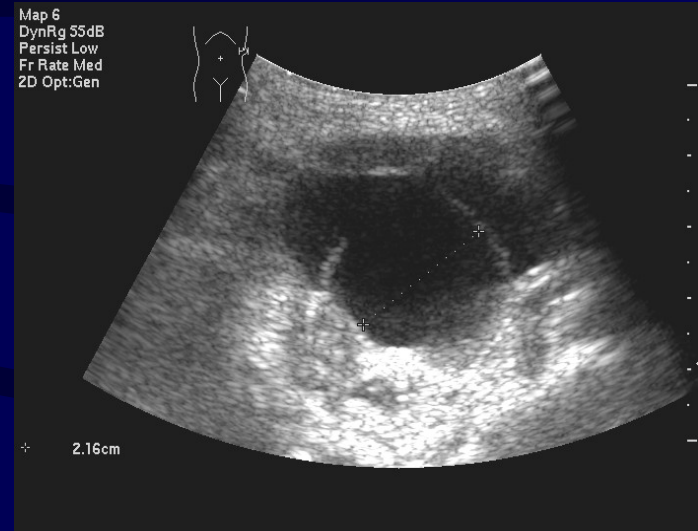
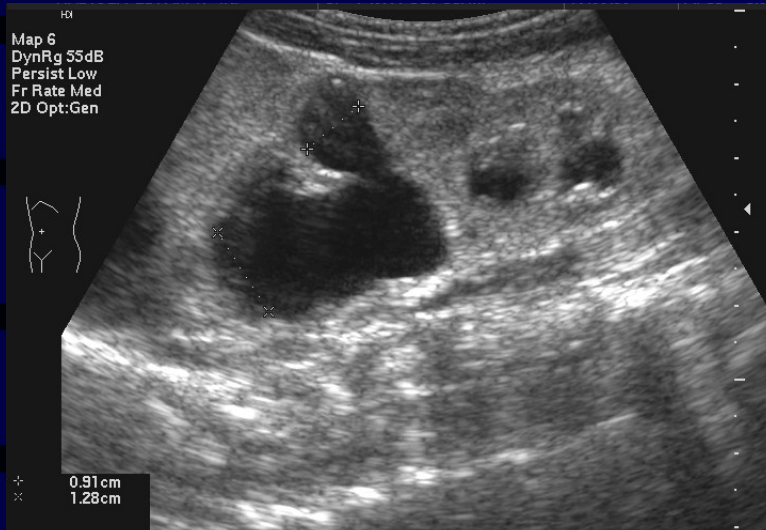POSTERIOR URETHRAL VALVE /NEONATAL/



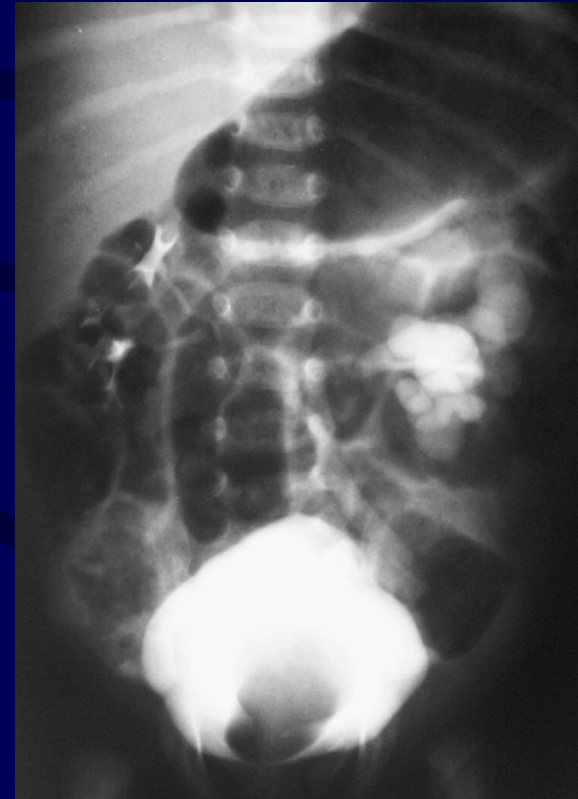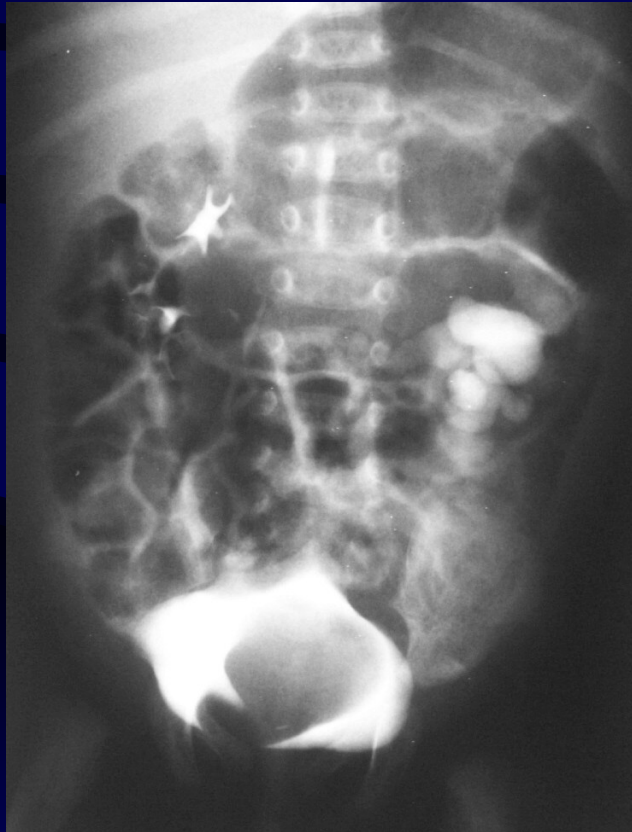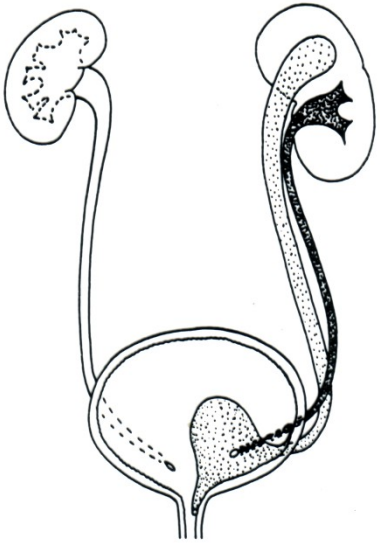
URETEROCELE SIMPLEX



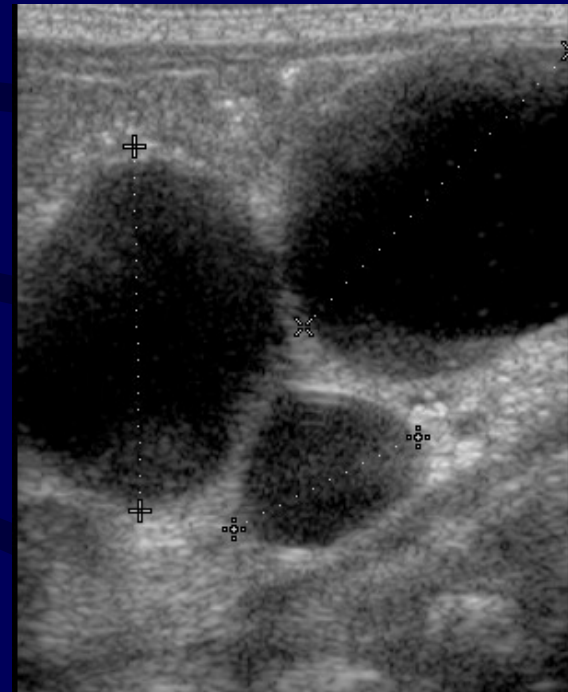
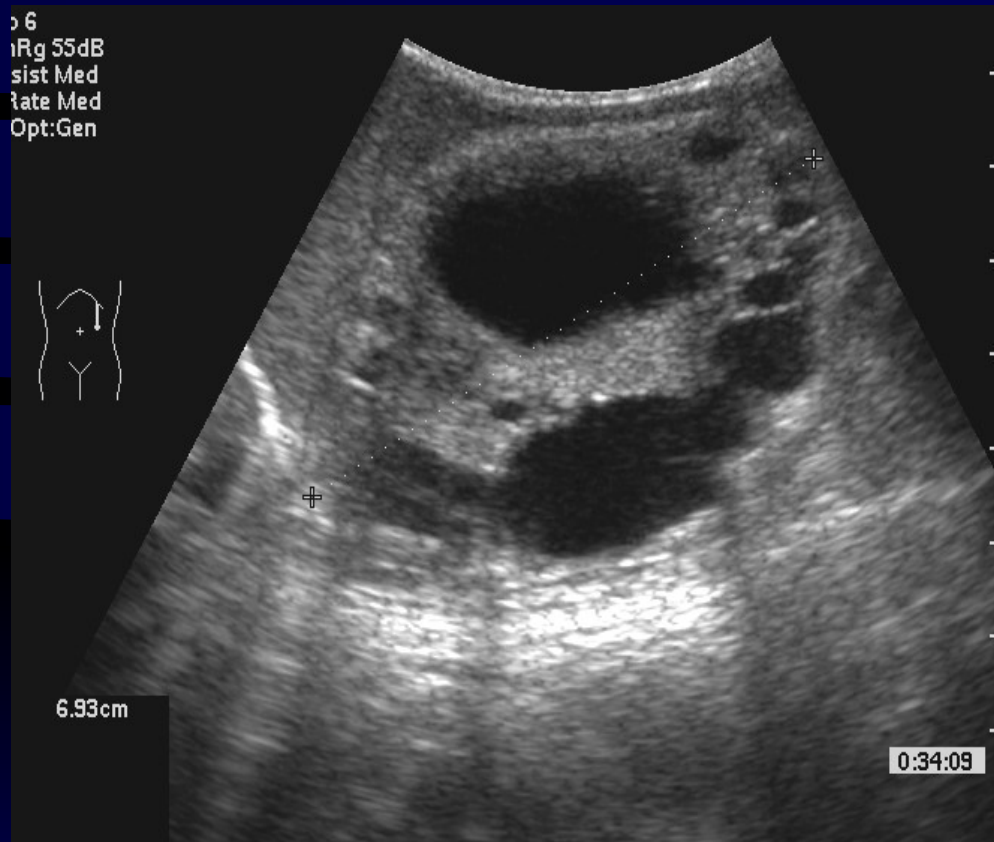ECTOPIC URETEROCELE



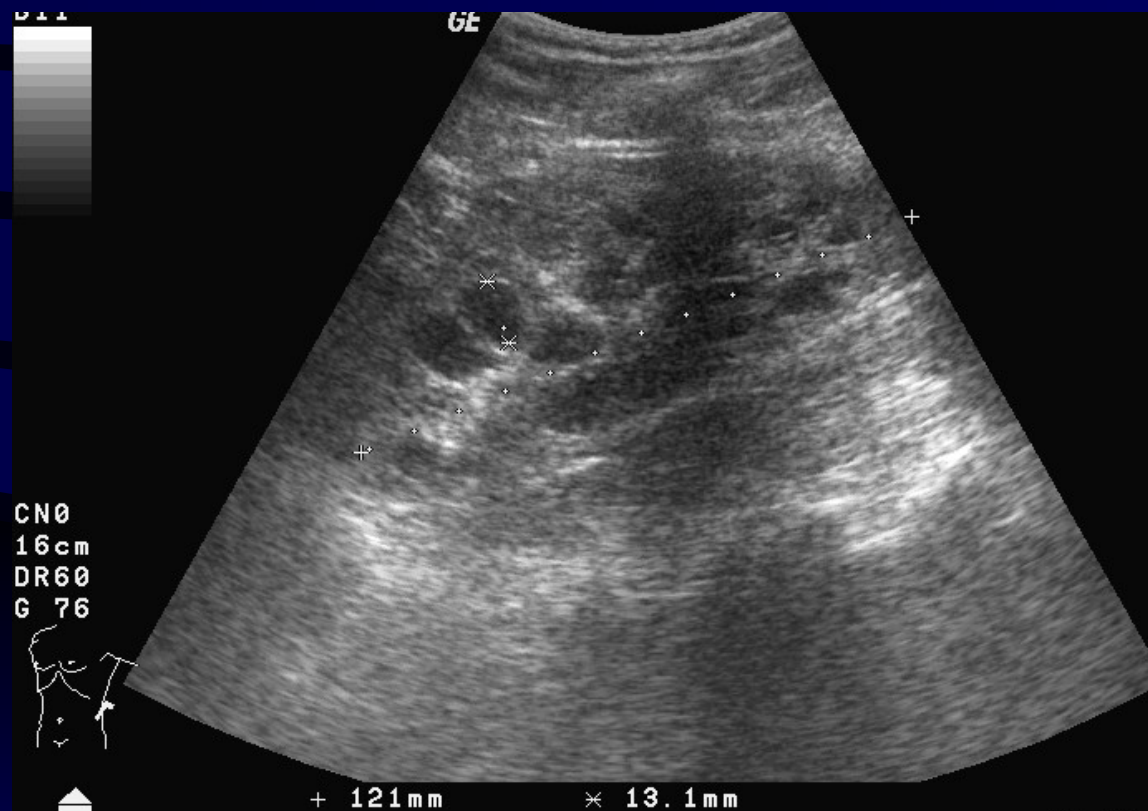ECTOPIC URETEROCELE



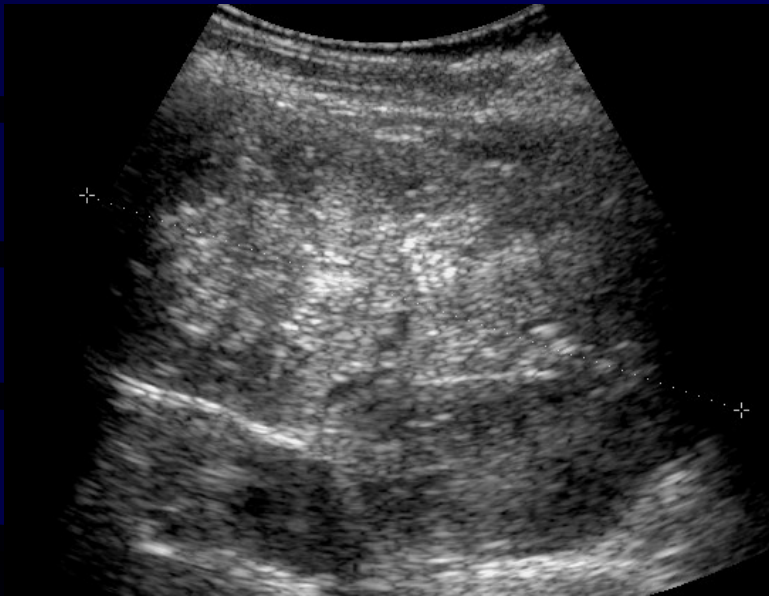
MULTICYSTIC DYSPLASTIC KIDNEY



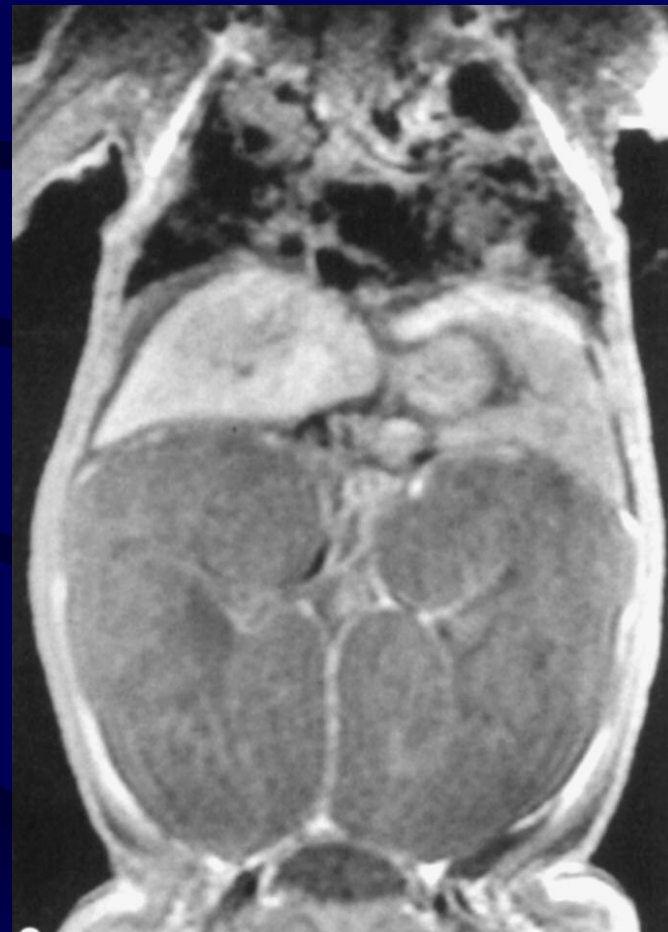CYSTIC KIDNEY DISEASE ADULT TYPE



CYSTIC KIDNEY DISEASE INFANTILE TYPE

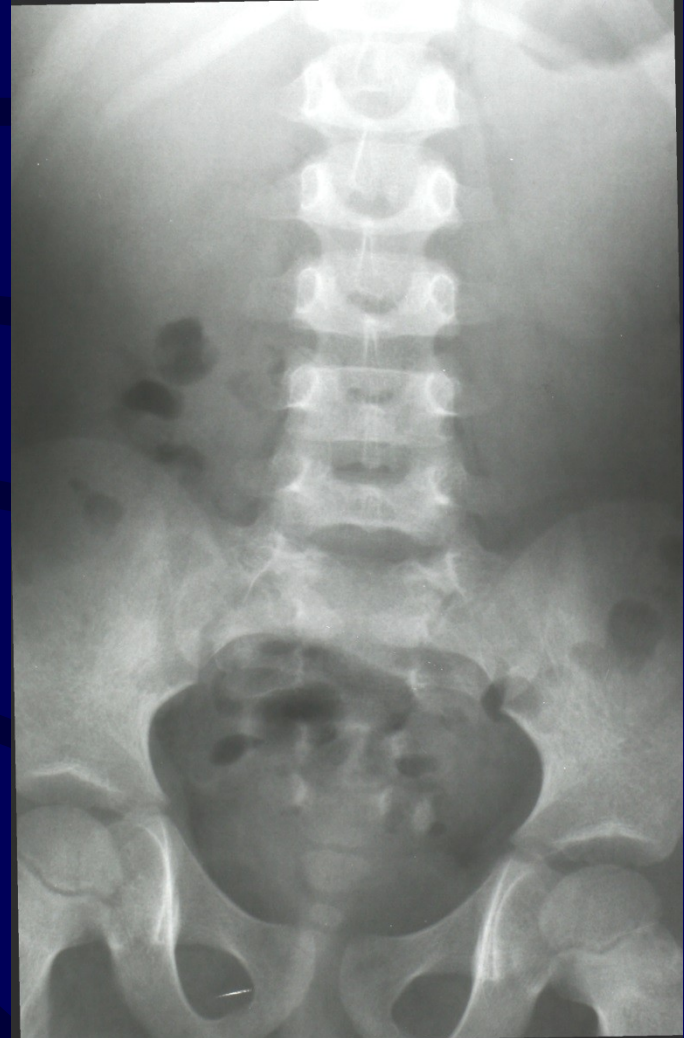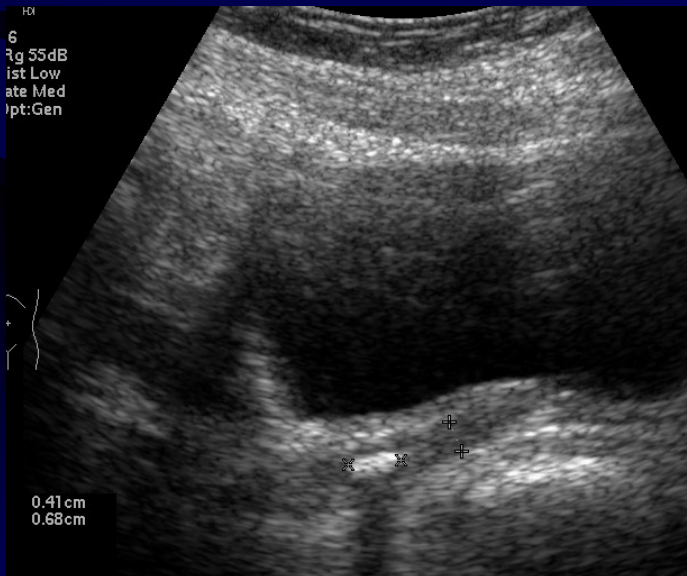

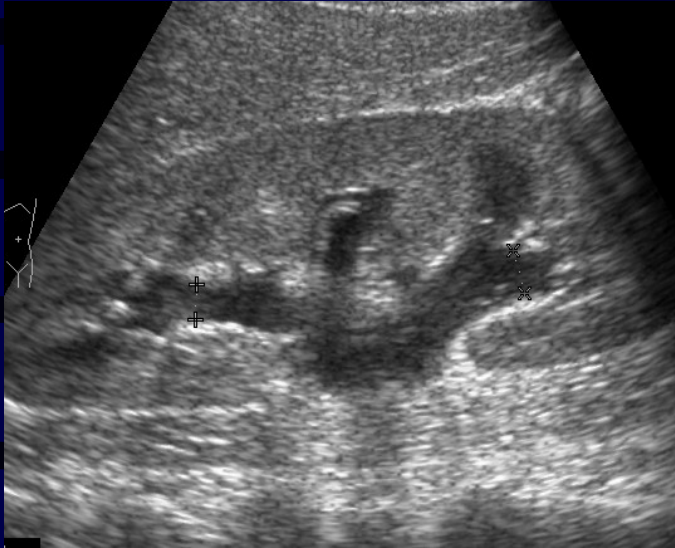
US

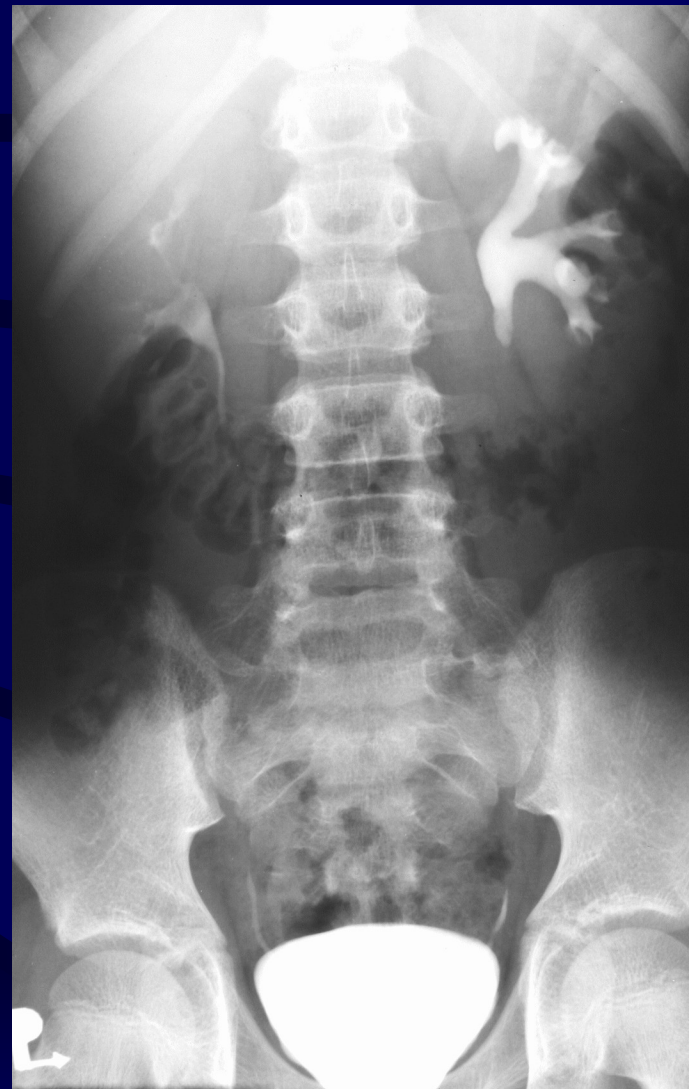
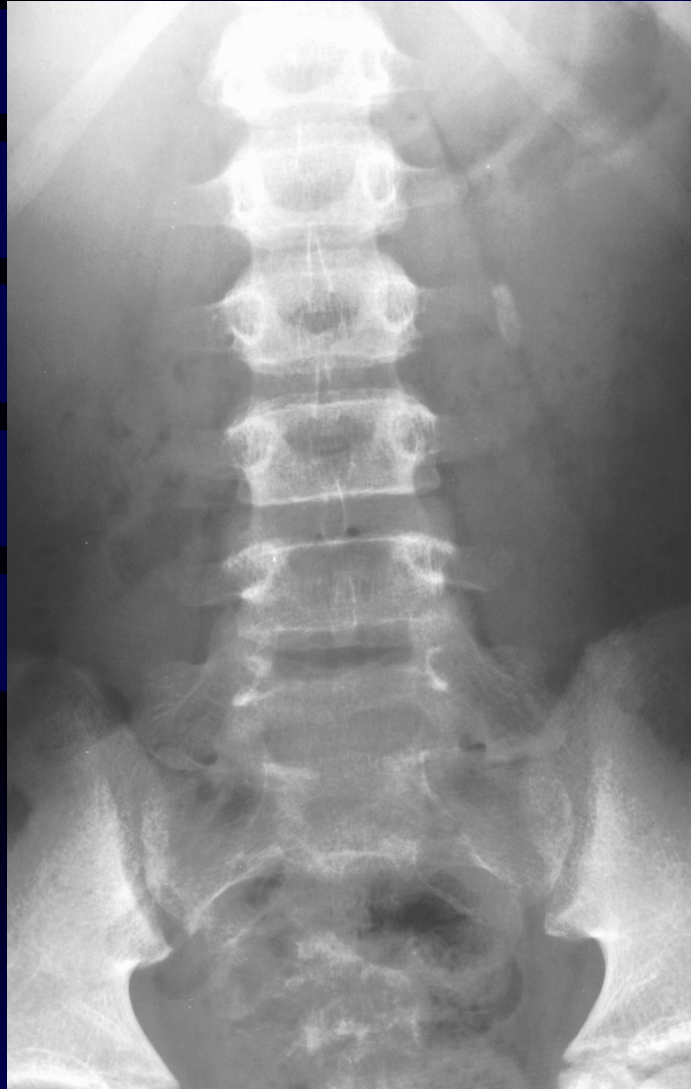
MR

URETEROLITHIASIS



URETEROLITHIASIS



MOST FREQUENT ABDOMINAL AND PELVIC MASSES

- **NEONATE**
 - **MULTICYSTIC KIDNEY**
 - **HYDRONEPHROSIS**
 - **URETERO-PELVIC JUNCTION OBSTRUCTION**
 - **URETERO-VESICAL JUNCTION OBSTRUCTION**
 - **REFLUX**
 - **POSTERIOR URETHRAL VALVE**
 - **URETEROCELE**

ABDOMINAL, PELVIC MASSES NEONATE

- **RETROPERITONEAL NON –RENAL**
 - **ADRENAL HEMORRHAGE**
 - **NEUROBLASTOMA**
 - **TERATOMA**
- **GASTROINTESTINAL**
 - **DUPLICATION**
 - **VOLVULUS**
- **GENITAL -**
HYDROMETROCOLPOS
OVARIAN

ABDOMINAL MASSES IN CHILDREN

1/12 – 2 yrs

- **HYDRONEPHROSIS**
- **WILMS TUMOR**
- **NEUROBLASTOMA**
- **TERATOMA**
- **GASTROINTESTINAL**
 - **INTUSSUSCEPTION**
 - **DUPLICATION**

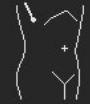ABDOMINAL MASSES

CHILDREN OLDER THAN 2 yrs

- **WILMS TUMOR**
- **NEUROBLASTOMA**
- **TERATOMA**
- **APPENDICEAL ABSCESS**
- **INTUSSUSCEPTION**

WILMS TUMOR

Map 6
DynRg 55dB
Persist Low
Fr Rate Med
2D Opt:Gen



9.09cm
6.05cm

Map 6
DynRg 55dB
Persist Low
Fr Rate Med
2D Opt:Gen



7.27cm

Map 6
DynRg 55dB
Persist Low
Fr Rate Med
2D Opt:Gen
CPA 84% Map 1
WF Med
PRF 1000 Hz
Flow Opt:Med V



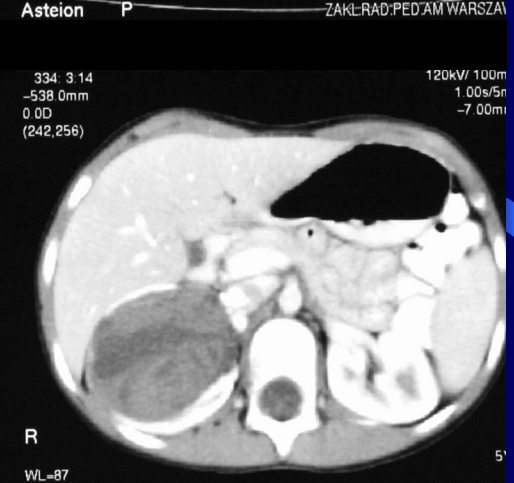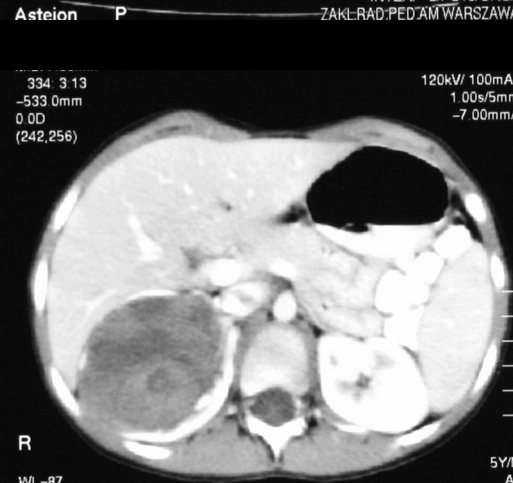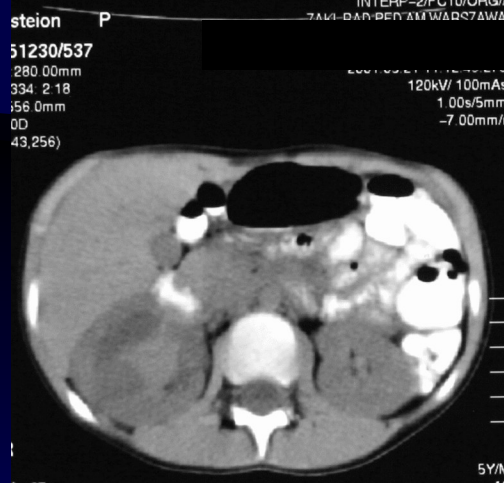
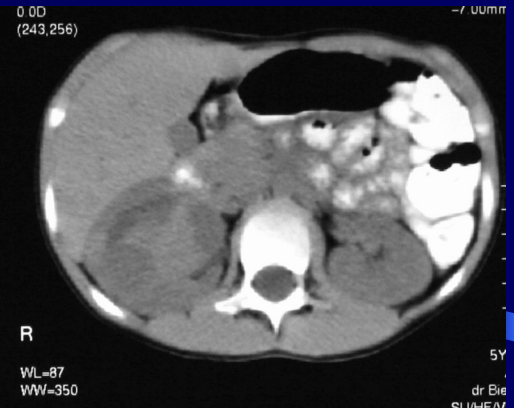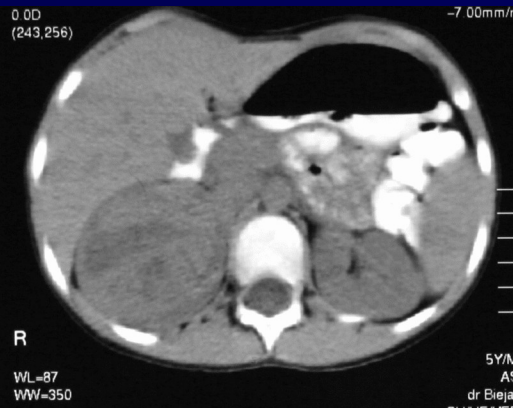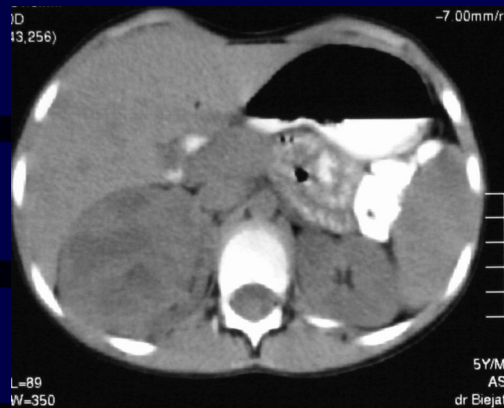5.46cm

Map 6
DynRg 55dB
Persist Low
Fr Rate Med
2D Opt:Gen

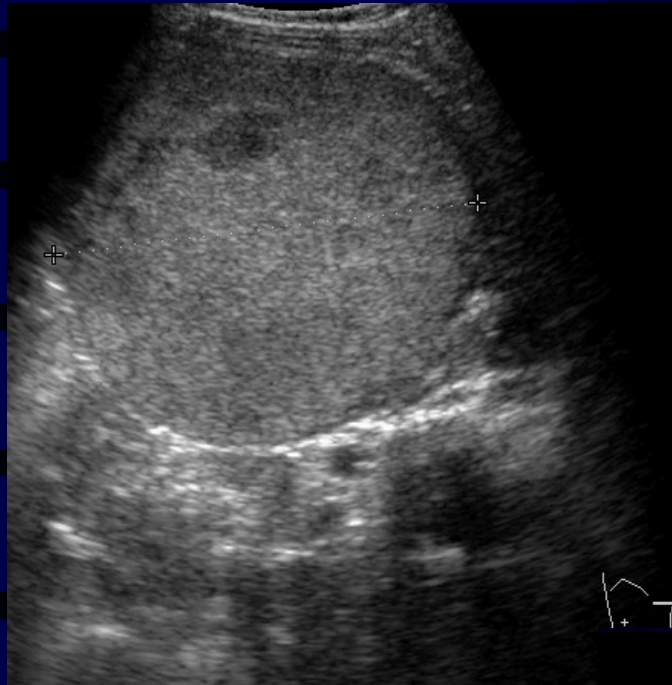


0:01:49

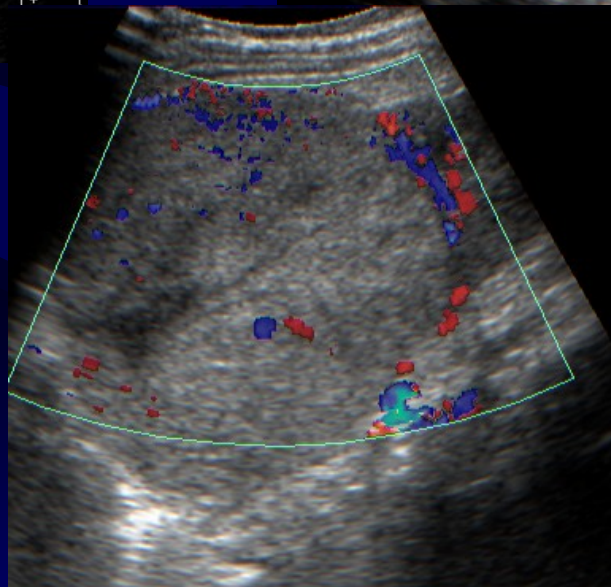
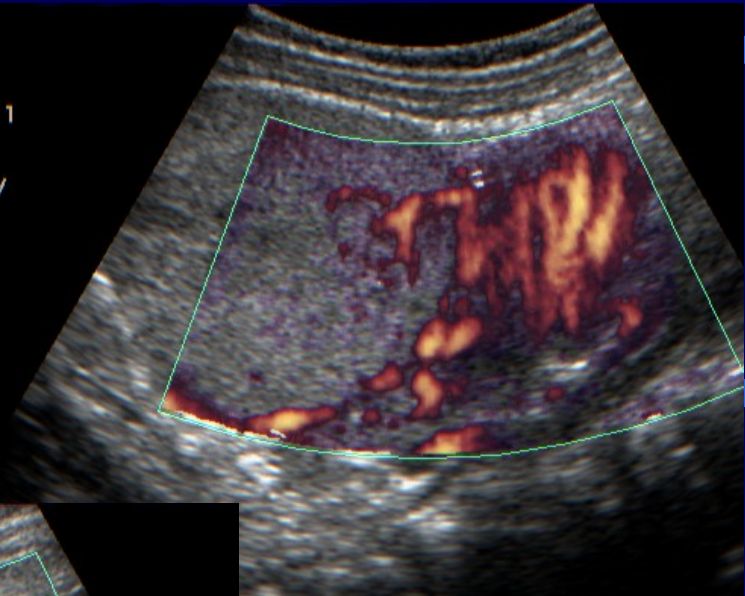
WILMS TUMOR CT



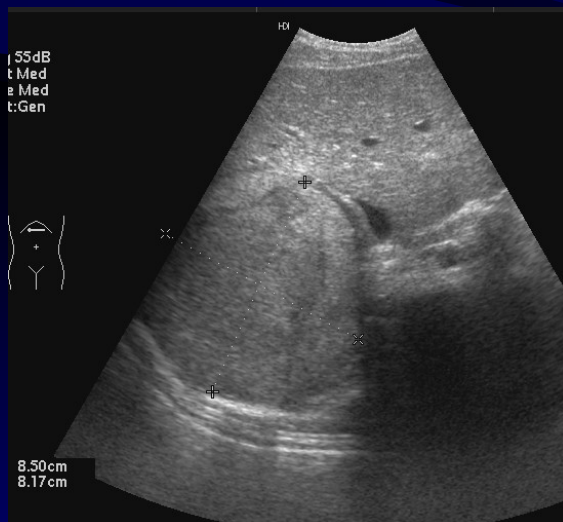
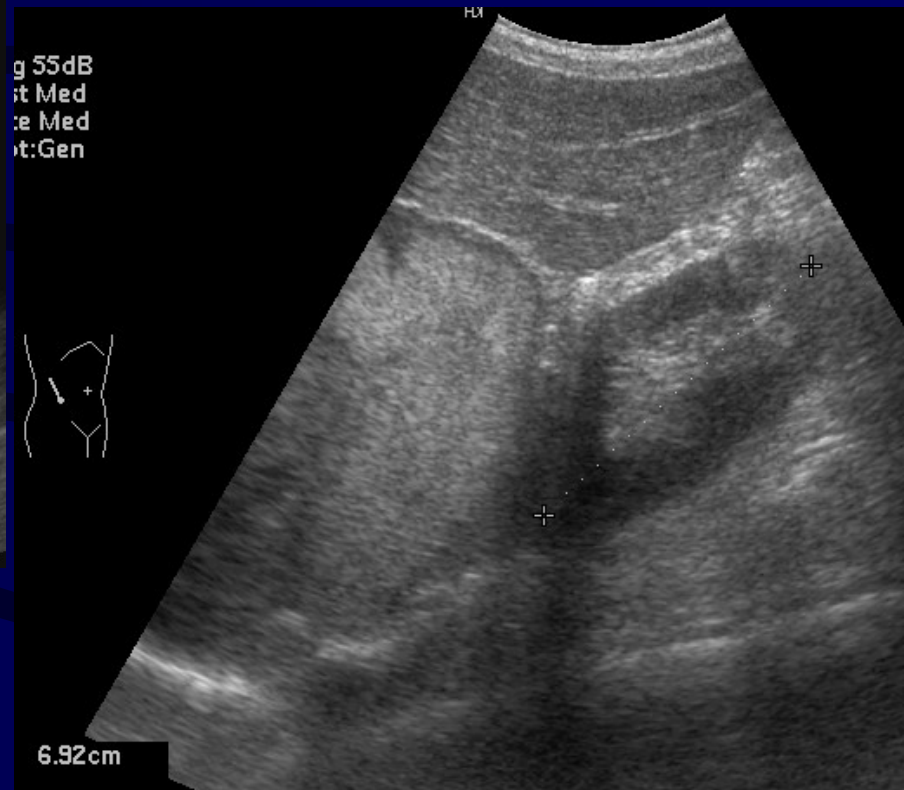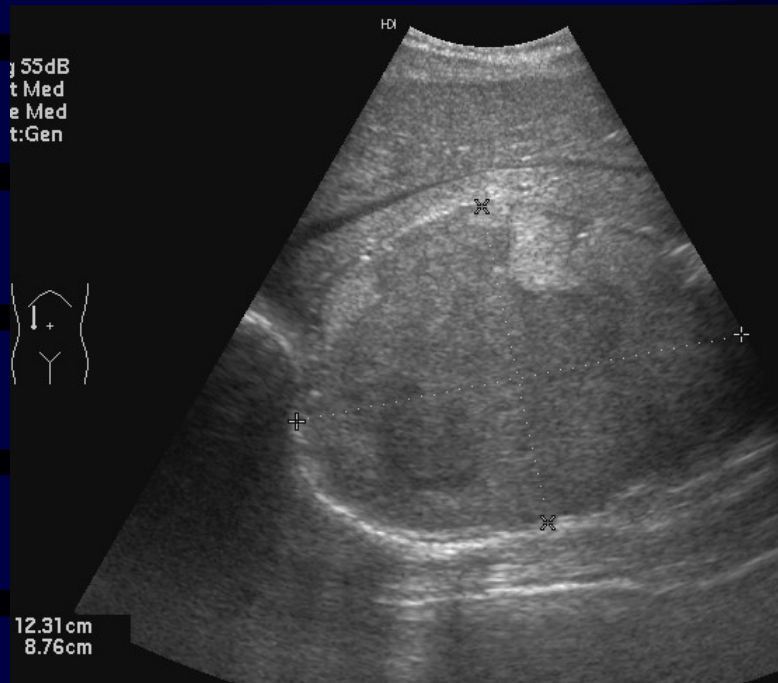WILMS TUMOR



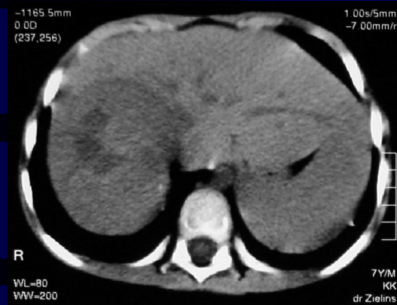
g 55as
st Low
te Med
pt:Gen
80% Map 1
led
1000 Hz
Opt:Med V



NEUROBLASTOMA

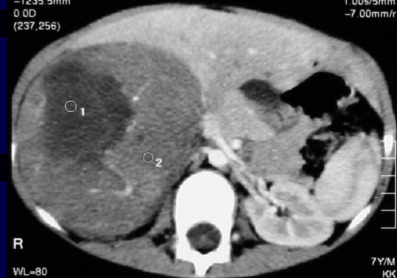

NEUROBLASTOMA CT



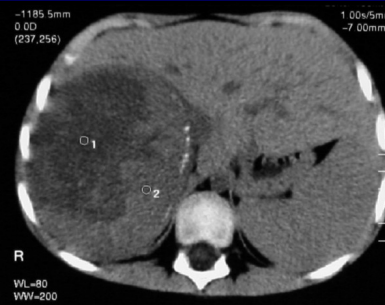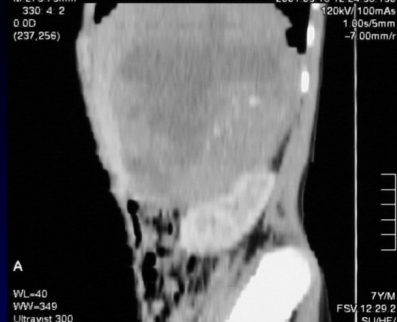Asteion P
931112/533
M 273 75mm
330 3 17
-1235 5mm
0 00
(237,256)

Lipka Kamil/onk/j.b
2001 05 18 12 25 09 578
120kV/ 100mAs
1 00s/5mm
-7 00mm/r



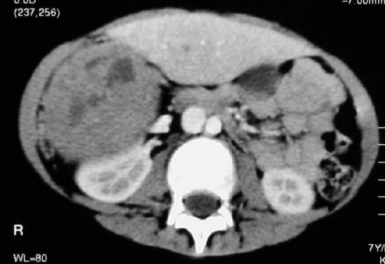Asteion P
931112/533
M 273 75mm
330 4 2
0 00
(237,256)

Lipka Kamil/onk/j.b
2001 05 18 12 24 58 150
120kV/ 100mAs
1 00s/5mm
-7 00mm/r



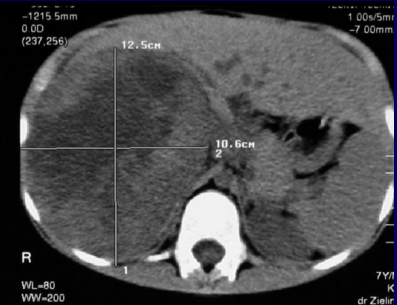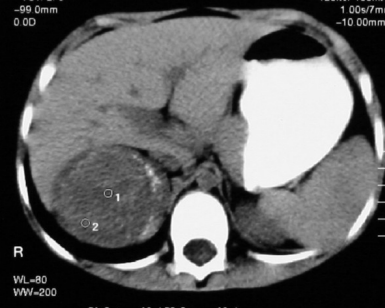Asteion P
931112/533
M 273 75mm
330 3 26
-1280 5mm
0 00
(237,256)

Lipka Kamil/onk/j.b
2001 05 18 12 25 16 007
120kV/ 100mAs
1 00s/5mm
-7 00mm/r



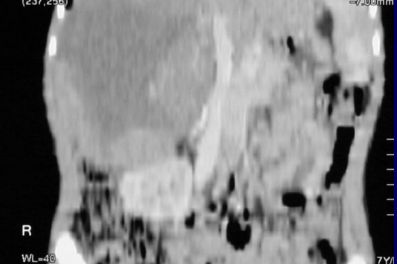
Asteion P
931112/851
M 272 50mm
781 2 9
-99 0mm
0 00

LIPKA KAMIL/j.brz/ONK
2001 10 10 10 28 35 300
120kV/ 100mAs
1 00s/7mm
-10 00mm/r



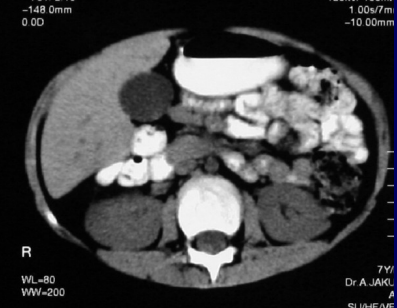Asteion P
931112/533
M 273 75mm
330 4 2
0 00
(237,256)

Lipka Kamil/onk/j.b
2001 05 18 12 24 58 15
120kV/ 100mAs
1 00s/5mm
-7 00mm/r

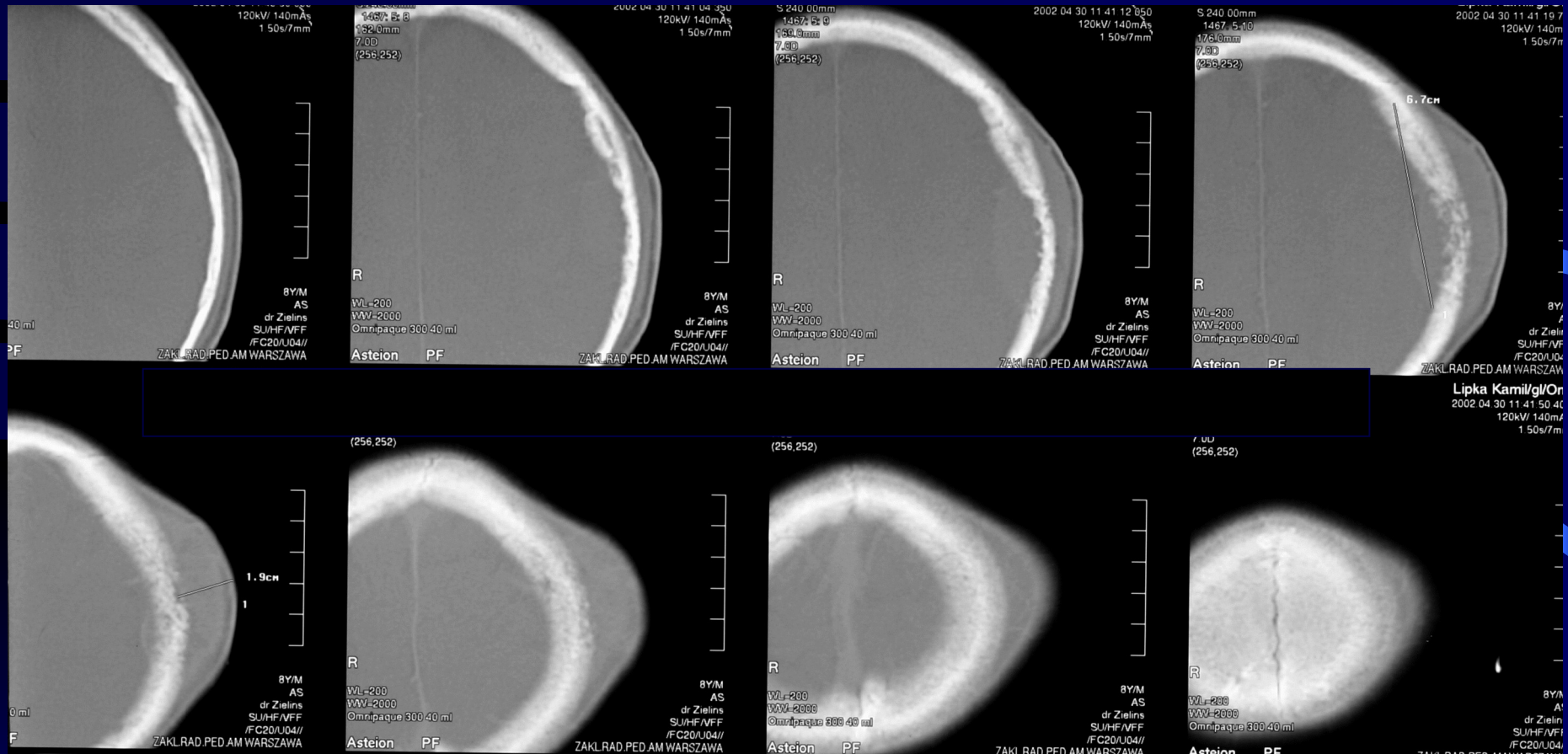


Asteion F
931112/851
M 272 50mm
781 2 16
-148 0mm
0 00

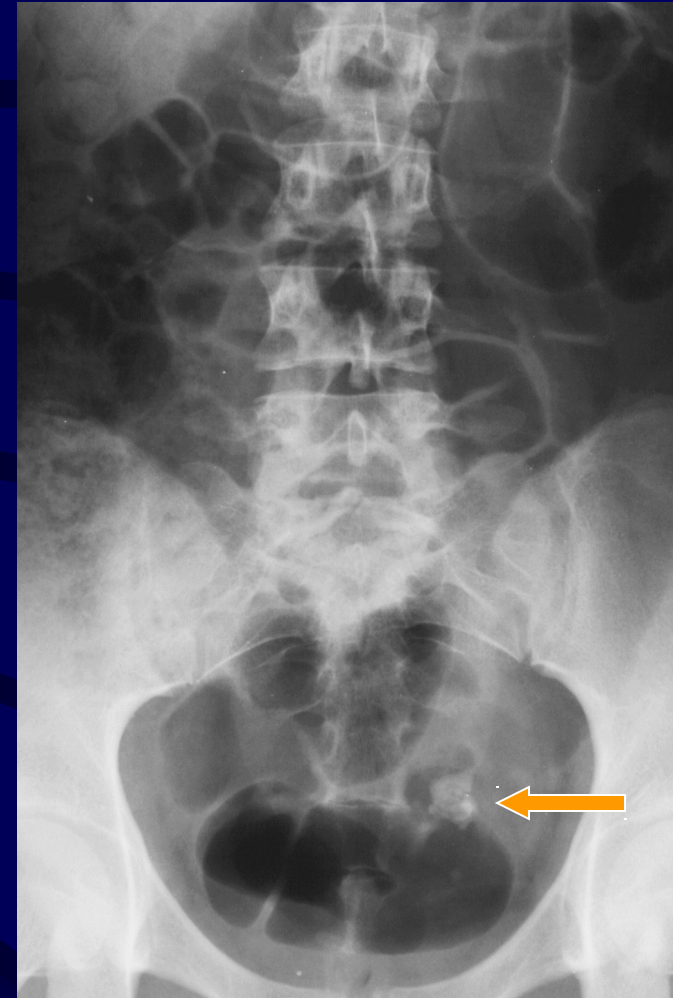
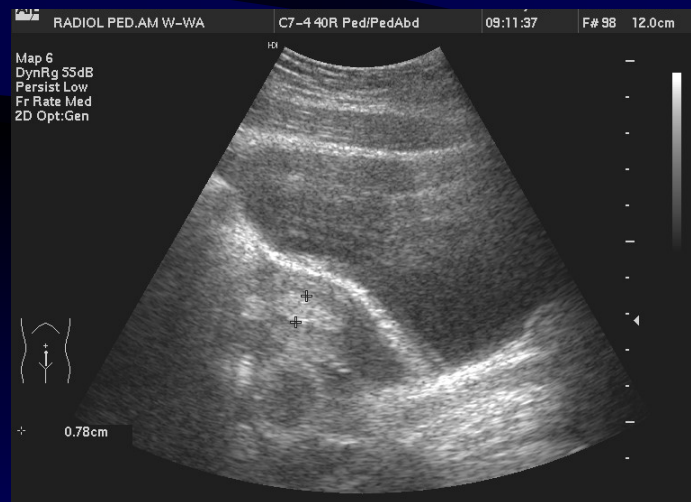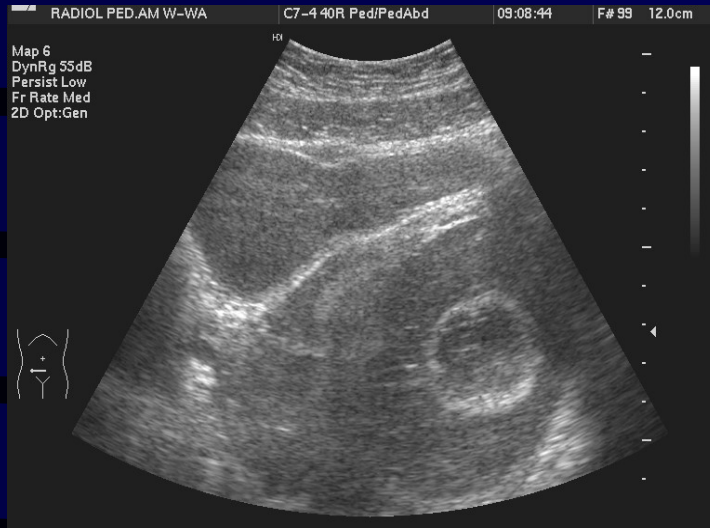LIPKA KAMIL/j.brz/ONK
2001 10 10 10 28 40 20
120kV/ 100mAs
1 00s/7mm
-10 00mm/r



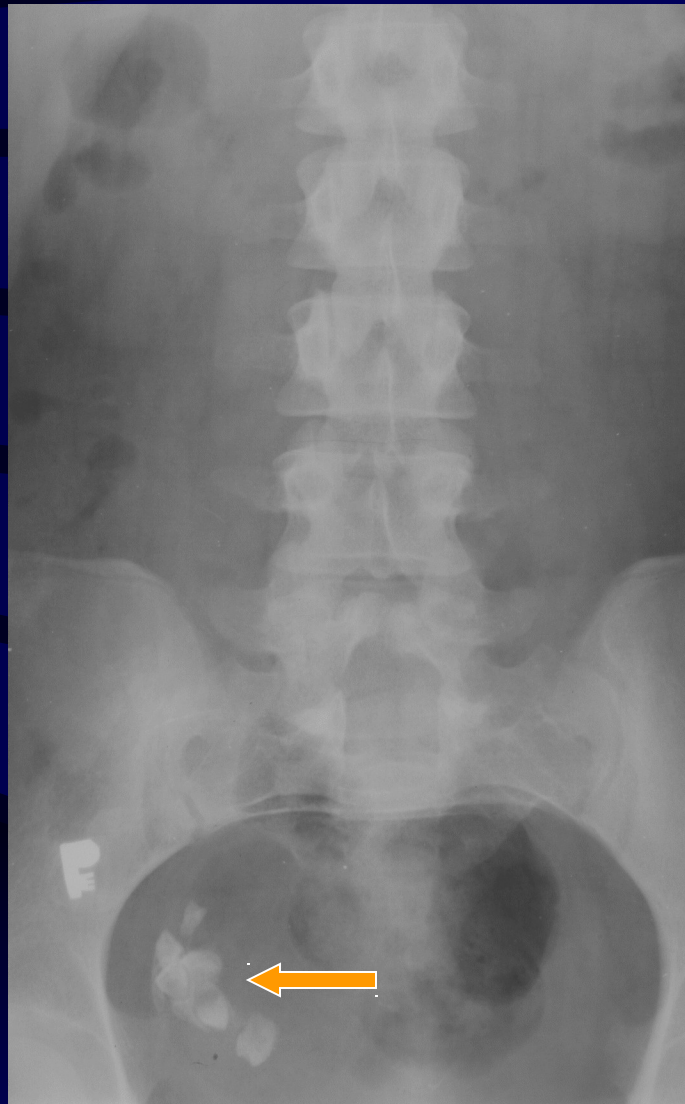
NEUROBLASTOMA - META



TERATOMA



TERATOMA



TERATOMA

